

## Hallmarks of liver lesions in pigs naturally infected by hepatitis E virus genotype 3<sup>1</sup>

Alex J.S. de Souza<sup>2,3</sup>, Andreza P. Malheiros<sup>3</sup>, Manoel do C.P. Soares<sup>3</sup>, Michele S. Gomes-Gouvêa<sup>4</sup>, João R.R. Pinho<sup>4</sup>, Washington L.A. Pereira<sup>5</sup> and Lilian R.M. Sá<sup>2\*</sup>

**ABSTRACT.**- De Souza A.J.S., Malheiros A.P., Soares M.C.P., Gomes-Gouvêa M.S., Pinho J.R.R., Pereira W.L.A. & Sá L.R.M. 2018. **Hallmarks of liver lesions in pigs naturally infected by hepatitis E virus genotype 3.** *Pesquisa Veterinária Brasileira* 38(1):65-70. Departamento de Patologia, Faculdade de Medicina Veterinária e Zootecnia, Universidade de São Paulo, Av. Prof. Dr. Orlando Marques de Paiva 87, São Paulo, SP 05508-270, Brazil. E-mail: [liliansa@usp.br](mailto:liliansa@usp.br)

Histopathological evaluation of liver from 33 pigs slaughtered for human consumption in Amazon region, previously tested by serology and molecular techniques for hepatitis E virus infection (HEV), was analysed in three groups: Group 1, negative for both HEV-RNA and anti-HEV IgG (n=10); Group 2, positive for HEV-RNA (n=13); Group 3, positive for anti-HEV IgG (n=10). Group 2 showed a significant difference among the groups for liver lesions such as lobular activity ( $P=0.007$ ), periportal interface hepatitis ( $P=0.004$ ), portal inflammation ( $P=0.028$ ) hepatitis with lobular, portal and periportal interface activity ( $P=0.001$ ). HEV detection by immunohistochemistry was performed and 3 of 6 samples of group 2 were positive. Pigs naturally infected by HEV genotype 3 present microscopic necroinflammatory liver lesions similar to HEV in humans. Liver histopathology showed be important in the diagnosis of active asymptomatic HEV infection in pigs slaughtered for human consumption because hepatic liver lesions may present distinct profiles according to molecular and serological diagnosis and in this sense, histopathology and immunohistochemistry may be an important complementary diagnostic tool.

INDEX TERMS: Liver, hepatitis E virus, genotype 3, hepatitis, histopathology, immunohistochemistry, swine, zoonosis, pathology.

**RESUMO.**- [Perfil das lesões histopatológicas hepáticas em suínos infectados naturalmente pelo genótipo 3 do vírus da hepatite E.] A avaliação histopatológica hepática de 33 suínos abatidos para consumo humano na região amazônica, previamente testados para infecção pelo vírus da hepatite E (HEV) por sorologia e técnicas moleculares, foi realizada em três grupos: Grupo 1, animais

negativos para HEV-RNA e anti-HEV IgG (n=10); Grupo 2, positivos para HEV-RNA (n=13); e Grupo 3, positivos para anti-HEV IgG (n=10). O grupo 2 apresentou diferenças estatísticas significantes entre os grupos em relação à presença de atividade lobular ( $P=0,007$ ), hepatite periportal de interface ( $P=0,004$ ), inflamação portal ( $P=0,028$ ) e atividade lobular acompanhada por inflamação portal e periportal de interface ( $P=0,001$ ). A detecção imunohistoquímica do HEV foi realizada e três de seis amostras do Grupo 2 foram positivas. Suínos naturalmente infectados pelo genótipo 3 do HEV apresentam lesões necroinflamatórias no fígado similares a lesão em humanos. A histopatologia hepática demonstrou ser importante no diagnóstico de infecção ativa e assintomática por HEV em suínos abatidos para consumo humano, pois as lesões no fígado apresentaram perfis diferenciados de acordo com o diagnóstico sorológico e molecular da infecção e, neste sentido, a histopatologia e imunohistoquímica podem representar importantes ferramentas complementares de diagnóstico.

<sup>1</sup> Received on August 23, 2016.

Accepted for publication on June 7, 2017.

<sup>2</sup> Departamento de Patologia, Faculdade de Medicina Veterinária e Zootecnia, Universidade de São Paulo (USP), Av. Prof. Dr. Orlando Marques de Paiva 87, Cidade Universitária, São Paulo, SP 05508-270, Brazil. \*Corresponding author: [liliansa@usp.br](mailto:liliansa@usp.br)

<sup>3</sup> Seção de Hepatologia, Instituto Evandro Chagas (IEC/SVS/MS), Tv. Almirante Barroso 492, Marco, Belém, PA 66093-020, Brazil

<sup>4</sup> Instituto de Medicina Tropical, Faculdade de Medicina, USP, Av. Dr. Enéas Carvalho de Aguiar 470, Jardim América, São Paulo, SP 05403-000.

<sup>5</sup> Instituto da Saúde e da Produção Animal, Universidade Federal Rural da Amazônia (UFRA), Av. Presidente Tancredo Neves 2501, Montese, Belém, PA 66077-830, Brazil.

TERMOS DE INDEXAÇÃO: *Genótipo 3, vírus da hepatite E, hepatite, histopatologia, imunohistoquímica, suínos, zoonose, patologia.*

## INTRODUCTION

The hepatitis E virus (HEV) is a non-enveloped RNA virus, taxonomically classified within *Hepeviridae* family, *Orthohepevirus* genus and species *Orthohepevirus A*, *Orthohepevirus B*, *Orthohepevirus C* and, *Orthohepevirus D*. It causes enterically transmissible hepatitis, which is regarded as an important emerging zoonosis in many regions of the world due to *Orthohepevirus A* genotypes 3 and 4 (Smith et al. 2014). Swine HEV isolates are classified within genotypes 3 and 4 (Smith et al. 2014). HEV genotype 3 is associated with sporadic cases of acute and chronic hepatitis E in humans from non-endemic regions of industrialized countries, where swine are the major source of human infections (Smith et al. 2014). HEV genotype 4 is only geographically distributed in Asia and some European industrialized countries (Meng 2010).

HEV infection in pigs is worldwide distributed but infected swine do not show clinical disease and/or macroscopic liver lesions (Meng 2010, De Souza et al. 2012). Features of hepatic lesions in pigs naturally infected by HEV genotypes 3 and 4 are still little described (Meng et al. 1997, Lee et al. 2007) although experimental studies in swine using isolates of genotype 3 documented microscopic hepatitis (Halbur et al. 2001, Schlosser et al. 2014). The aim of this study is to describe the main histopathological liver lesions in naturally HEV genotype 3 infected pigs, which were slaughtered for human consumption in the Eastern Brazilian Amazon, a HEV non-endemic region. This study was approved by the Ethics Committee for Animal Research of Evandro Chagas Institute, Belém, Pará, Brazil (No. 0019/2010/CEPAN/IEC/SVS/MS).

## MATERIALS AND METHODS

This study included 33 (n=33) pig liver samples (obtained from animals with estimated age of 6 months) selected from a previous HEV study that evaluated HEV infection among 151 pigs slaughtered for human consumption in the Eastern Brazilian Amazon (De Souza et al. 2012). Eighteen samples were collected in one officially registered slaughterhouse and 15 in three smaller and unofficial facilities where pigs were produced in small-scale family farms and slaughtered for direct sale in local open-air markets (De Souza et al. 2012).

The 151 pigs were tested for HEV-RNA detection by nested RT-PCR in serum, stool and liver samples and tested for anti-HEV IgM and IgG antibodies in serum samples by ELISA, under previously described conditions (De Souza et al. 2012). Briefly, the molecular screening for HEV-RNA in pig samples was developed using primer sets for partial amplification of ORF1 and ORF2 HEV genomic regions: the amplification of ORF1 region (287 bp) was developed using the external primers Cons-ORF1-s1 (5'-CTGGCATACTACTGCTGAGC-3') and ConsORF1-a1 (5'-CCATCRARRCAGTAAGTGCGGTC-3') and internal primers ConsORF1-s2 (5'-CTGCCYTKGCGAATGCTGTGG-3') and ConsORF1-a2 (5'-GGCAGWRTACCARGCTGAACATC-3') (Wang et al. 1999); ORF2 region (348 bp) was amplified using the external primers 3156NF (5'-AATTATGCYAGTAYCGRGTTG-3') and 3157NR (5'-CCCTTRTCYTGCTGMGCATTCTC-3') and internal primers 3158NF (5'-GTWATGCTYTGCATWCATGGCT-3') and 3159NR

(5'-AGCCGACGAAATCAATTCTGTC-3') (Huang et al. 2002). Swine samples with HEV-RNA positive results were sequenced and subjected to phylogenetic analysis which confirmed that pigs were infected by HEV genotype 3 isolates (De Souza et al. 2012).

The 33 swine liver samples were distributed into three groups according to molecular and serological results for HEV infection by animal: group 1 (control group) negative for both HEV-RNA and anti-HEV IgG (n=10); group 2, positive for HEV-RNA and negative or positive for anti-HEV IgG animals (n=13); group 3, positive only for anti-HEV IgG and negative for HEV-RNA (n=10). All 33 liver samples were negative for porcine circovirus type 2 by PCR.

Liver fragments were fixed in 10% buffered formalin and 4 µm thick paraffin sections were stained with hematoxylin and eosin (HE). All slides were examined independently by pathologists (L.R.M.S. and A.J.S.S) blinded to the identity of the case. The microscopic evaluation was performed under a light microscope coupled to a digital camera (Eclipse Ni-U and DS-U3 cooled digital camera, Nikon, Japan). Degenerative, necroinflammatory, vascular, pigmentary and fibrosis lesions in liver acinus, portal spaces, and the biliary tract were semiquantitatively graded on a scale of 0-3, where: 0=absence of injury; 1 = mild; 2 = moderate; and 3 = severe lesion. The hepatic morphological diagnoses were classified into: A = fragment within normal histology; B = lobular activity (multifocal randomly distributed inflammatory areas within lobules containing inflammatory cells associated with focal spotty necrosis); C = portal hepatitis (portal tracts expanded by inflammatory infiltrate); D = lobular activity with portal and periportal interface activity (inflammatory infiltrate extending the portal tract with erosion or loss of the hepatic parenchyma at periportal limiting plate), and E = focal eosinophilic chronic hepatitis, which was considered to be caused by migration of larval helminth parasites (Longerich & Schirmacher 2008, Cullen 2009, Cullen & Stalker 2015).

For immunohistochemical (IHC) detection, 4 µm liver sections of group 2 (n=6) and group 1 (n=1) were used. Briefly, after endogenous peroxidase blocked, antigen retrieval using citrate buffer pH 6.0 and non-specific protein blocked were applied. The rabbit polyclonal Anti-Hepatitis E Virus ORF3 antibody (Bioss, USA) was incubated overnight at 4°C. The detection system applied was a biotin-free polymer technique (Novolink™, Leica), and diaminobenzidine (DAB) used as chromogen and hematoxylin as a counterstain. Histological sections from one case of group 1 and a liver HEV-RNA positive sample, were used as negative controls substituting the primary antibody for PBS at pH 7.4. Presence of HEV antigen was assessed according to the intensity and distribution between zones and cell types involved. The positivity criterion was presence of slightly golden-brown intracytoplasmic granula.

The comparison among variables was performed using the Kruskal-Wallis test and Dunnett's post test with a significance level of 5%. All tests were performed using two-tailed analysis (GraphPad PRISM™ software, version 6).

## RESULTS

Data analyses of histopathological lesions of 33 cases are summarised in the Table 1. Liver samples from group 1 were unremarkable in 50% (5/10) (Fig.1), five cases showed mild multifocal acute lobular inflammatory infiltrate composed by eosinophils, neutrophils and lymphocytes. HEV antigens were negative by IHC in the negative controls.

The frequency of lobular activity was 92.3% in group 2 (12/13), with a significant difference among the other groups ( $P=0.007$ ) and periportal interface hepatitis oc-



markable; 36.4% (12/33) corresponded to lobular activity; 6% (2/33) to portal hepatitis; 15.2% (5/33) consisted of lobular activity with portal and periportal interface hepatitis; 6% (2/33) corresponded to focal eosinophilic chronic hepatitis. There was a significant difference ( $P = 0.001$ ) in the morphological diagnoses among the groups. Group 2 presented significant difference when compared to groups 1 and 3. One sample of group 2 (case 12) showed mild lobular activity and portal hepatitis associated with multifocal mild swelling hepatocytes, and multifocal lymphoid aggregates in the centrilobular region (Fig.5) and in particular, this sample was the only one with HEV-RNA and anti-HEV IgG positivity.

Immunohistochemistry detection of HEV ORF3 protein (pORF3) was positive in 50% (3/6) of liver cases from group 2, with different distribution of pORF3 immunostaining. In case 21, pORF3 was cytoplasmatic immunostained and was

mildly detected in normal hepatocytes and Kupffer cells, which were randomly distributed (Fig.6); in the cases 13 and 19, mild immunostaining was also observed in biliary epithelium cells, or leukocytes, in the portal spaces (Fig.7). No immunologic labelling was observed in the degenerating and/or necrotic cells. Negative control cases were negative for pORF3 immunostaining in any cell.

## DISCUSSION

The swine liver samples evaluated in this study were positive for HEV genotype 3 that represents the most common genotype that infects pigs used for human consumption. HEV-RNA positive swine showed microscopic hepatic lesions characterized by acute activity and/or portal hepatitis, statistically different from HEV negative samples. Histopathological liver lesions analysis can be used in the complementary diagnosis of natural swine HEV infection

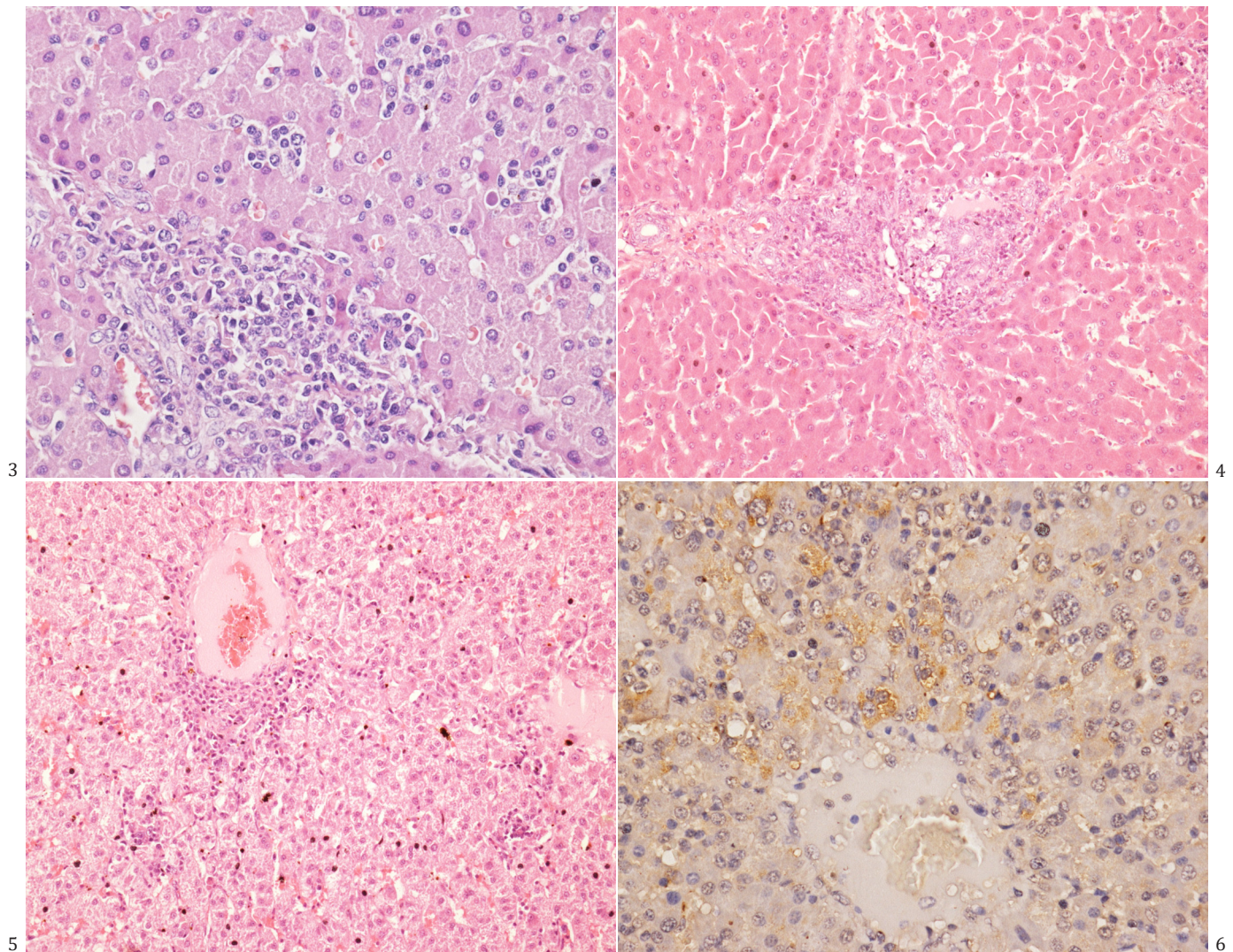


Fig.3. Liver, group 2 (case 21), periportal interface hepatitis. Necrotic periportal hepatocytes surrounded by mononuclear cells, HE, obj.40x.

Fig.5. Liver, group 2 (case 12), mild lymphoplasmacytic lobular activity and lymphoid aggregate next to centrilobular hepatic vein. HE, obj.20x.

Fig.4. Liver, group 3 (case 32), lymphoplasmacytic portal hepatitis and absent lobular activity. HE, obj.20x.

Fig.6. Liver, group 2 (case 21), intracytoplasmic granular golden-brown positive immunostaining in hepatocytes for polyclonal anti-HEV pORF3. Hematoxylin as counterstain, obj.40x.

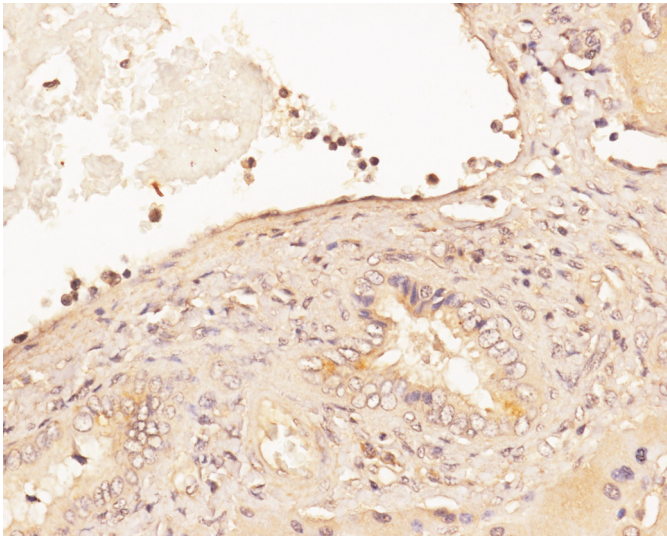


Fig.7. Liver, group 2 (case No. 13), pORF3 was cytoplasmatic immunostained in biliary epithelium cells in the portal spaces. Hematoxylin as a counterstain, 40x;

and may lead to a more complete understanding of HEV pathogenesis in comparative pathology studies.

Despite zoonotic characteristics of HEV genotypes 3 isolates, HEV induced microscopic liver lesions that can be different in humans and pigs. In humans, descriptions of acute liver injury caused by HEV genotype 3 are based on studies of isolated cases and can be differentiated from swine hepatic lesions described here. They generally show moderate to severe necroinflammatory hepatocellular lesions; in addition to a large involvement of the biliary tract with cholestatic hepatitis and destructive cholangitis, which may eventually progress to fulminant hepatitis (Meng 2010). Although, liver histopathology of acute autochthonous hepatitis E in humans includes remarkable confluent necrosis, Kupffer cell aggregates with hemosiderosis, occasionally portal tract and acinar polymorphonuclear infiltrate, lobular architecture disruption with rosette formation, ballooning and apoptotic bodies formation, and mitotic figures in hepatocytes in panacinar distribution (Meng 2010). In addition, chronic lesion described in human liver infected by HEV, including fibrosis and cirrhosis, is complete different from pig responses, which are characterised by mild to moderate acute self-limiting hepatitis such as described and don't progress to chronic liver disease (Meng et al. 1998a, 1998b, Meng 2010). Moreover, distinct hepatic lesions in humans and pigs infected by phylogenetically related isolates of HEV genotype 3 may occur due to an increased viral load of infection and specific host immune responses (Meng et al. 1998a, 1998b, Meng 2010).

Group 2 showed mild to moderate lobular activity and portal hepatitis associated with periportal interface hepatitis. These microscopic lesions were reported before, but did not systematically described in piglets naturally infected by HEV in the United States of America (Meng et al. 1997) and South Korea (Lee et al. 2007). Moreover, the profile of liver lesions can be related to host response, virus load and infection phase (Meng 2010) as we pointed in the systematic analysis of the hepatic lesions.

Pigs at 3 to 4 months of life with positive detection of HEV-RNA in the liver, bile and faeces may present moderate degree of liver inflammatory activity, indicating an acute pattern of injury prior to seroconversion to anti-HEV IgG (De Deus et al. 2007, 2008, Meng 2010). Lobular activity and portal hepatitis have also been previously experimentally demonstrated in the early stages of infection in chimpanzees inoculated with HEV (Yu et al. 2010) and; thus, the data of an acute hepatitis pattern seems to be directly related to HEV-RNA detection in the liver of naturally (Lee et al. 2007) and experimentally infected pigs (Halbur et al. 2001, Schlosser et al. 2014).

HEV exposure phase and hepatic lesions were not clearly related. We believe that lesion patterns of pigs from group 3 might indicate that these animals may have been exposed to HEV in early stages of life, predominantly in the post-weaning stages (at 2 to 3 months of age) (De Deus et al. 2007). This leads to later infections at slaughter, evidenced by the seropositivity for anti-HEV IgG and negative HEV-RNA and absence of acute necroinflammatory lesion in the liver (De Deus et al. 2007). Mild portal hepatitis and unremarkable livers in group 3 may be an indication of a possible recovery from acute inflammatory lesions prior to seroconversion. Another hypothesis could be that a very low viral load would stimulate seroconversion without hepatic lesions (Meng et al. 1998a, Meng 2010).

Here, the IHC detection of HEV antigens in the cases had similar slightly granular intracytoplasmic pattern with multifocal distribution, predominantly in non-degenerate hepatocytes such as described by other authors (Ha & Chae 2004, Gupta et al. 2012). HEV antigens (pORF3) were also observed in Kupffer cells and biliary epithelium in our cases, which is similar to the results of HEV immunostaining in humans (Gupta et al. 2012). On the other hand, wild boars and miniature pigs experimentally infected with an isolate of wild boar genotype 3 HEV presented liver immunostaining of pORF2 ranging from mild to marked mainly in Kupffer cells and liver sinusoidal endothelial cells (Schlosser et al. 2014).

Failure to observe viral antigens in degenerated or necrotic hepatocytes indicates that cellular damage has not been caused by a direct cytopathic effect of HEV replication (Ha & Chae 2004). The pathogenesis of HEV-induced hepatic lesions is not completely understood; however it has non-cytopathic origin and appears to correspond to a pattern of cellular immune responses by the host (Gupta et al. 2012). Although, only 3 of 6 liver tested were positive in the IHC for HEV detection; this result differs from previous research, which indicated a large consistency between IHC and HEV-RNA molecular detection (Ha & Chae 2004, Gupta et al. 2012). Differences between HEV immunostaining in liver may be related to primary antibodies' sensitivity between pORF2 and pORF3 (Gupta et al. 2012) and/or course of infection.

In conclusion, naturally infected pigs with HEV genotype 3, in the absence of macroscopic alterations, may present microscopic necroinflammatory liver lesions compatible with acute viral hepatitis, similar to HEV infection in humans. There is potential risk for occupational and/or

meat consumption related to HEV infections regarding the difficult of detect positive cases during slaughter. Additionally, the results point that HEV-infected swine showed much higher frequency of liver lesions than initially suspected and the complementary use of molecular, serological, histopathological and immunohistochemical techniques may provide relevant contributions to understanding of HEV natural infection in swine and other species.

**Acknowledgements.**- We thank Dr. Carla Pagliari from Laboratório de Doenças Infecciosas e Transmissíveis, Faculdade de Medicina, Universidade de São Paulo for its significant contribution related to immunohistochemistry. This study was partially funded by “Conselho Nacional de Desenvolvimento Científico e Tecnológico” (CNPq, 141398/2015-9).

**Conflict of interest.**- The authors declare that they have no conflicts of interest.

## REFERENCES

- Cullen J.M. 2009. Summary of the world small animal veterinary association standardization committee guide to classification of liver disease in dogs and cats. *Vet. Clin. Small Anim.* 39:395-418.
- Cullen J.M. & Stalker M.J. 2015. Liver and biliary system, p.259-352. In: Maxie M.G. (Ed.), Jubb, Kennedy, Palmer's Pathology of Domestic Animal. Vol.2. 6th ed. Elsevier, Philadelphia.
- De Deus N., Seminati C., Pina S., Mateu E., Martín M. & Segalés J. 2007. Detection of hepatitis E virus in liver, mesenteric lymph node, serum, bile and faeces of naturally infected pigs affected by different pathological conditions. *Vet. Microbiol.* 119:105-114.
- De Deus N., Casas M., Peralta B., Nofrarías M., Pina S., Martín M. & Segalés J. 2008. Hepatitis E virus infection dynamics and organic distribution in naturally infected pigs in a farrow-to-finish farm. *Vet. Microbiol.* 132:19-28.
- De Souza A.J.S., Gomes-Gouvêa M.S., Soares M.C.P., Pinho J.R.R., Malheiros A.P., Carneiro L.A., dos Santos D.R. & Pereira W.L.A. 2012. HEV infection in swine from Eastern Brazilian Amazon: Evidence of co-infection by different subtypes. *Comp. Immunol. Microbiol. Infect. Dis.* 35:447-485.
- Gupta P., Jagya N., Pabhu S.B., Durgapal H., Acharya S.K. & Panda S.K. 2012. Immunohistochemistry for the diagnosis of hepatitis E virus infection. *J. Viral Hepat.* 19:177-183.
- Ha S.K. & Chae C. 2004. Immunohistochemistry for the detection of swine hepatitis E virus in the liver. *J. Viral Hepat.* 11:263-267.
- Halbur P.G., Kasorndorkbua C., Gilbert C., Guenette D., Potters M.B., Purcell R.H., Emerson S.U., Toth T.E. & Meng X.J. 2001. Comparative pathogenesis of infection of pigs with hepatitis E viruses recovered from a pig and a human. *J. Clin. Microbiol.* 39:918-923.
- Huang F.F., Haqshenas G., Guenette D.K., Halbur P.G., Schommer S.K., Pierson F.W., Toth T.E. & Meng X.J. 2002. Detection by reverse transcription-PCR and genetic characterization of field isolates of swine hepatitis E virus from pigs in different geographic regions of the United States. *J. Clin. Microbiol.* 40:1326-1332.
- Lee S.H., Kang S.C., Kim D.Y., Bae J.H. & Kim J.H. 2007. Detection of swine hepatitis E virus in the porcine hepatic lesion in Jeju Island. *J. Vet. Sci.* 8:51-55.
- Longerich T. & Schirmacher P. 2008. Comparative Pathology, p. 47-73. In: Weber O. & Protzer U. (Eds), *Comparative Hepatitis*. Birkhäuser, Berlin.
- Meng X.J., Purcell R.H., Halbur P.G., Lehman J.R., Webb D.M., Tsareva T.S., Haynes J.S., Thacker B.J. & Emerson S.U. 1997. A novel virus in swine is closely related to the human hepatitis E virus. *Proc. Natl Acad. Sci. USA* 94:9860-9865.
- Meng X.J., Halbur P.G., Haynes J.S., Tsareva T.S., Bruna J.D., Royer R.L., Purcell R.H. & Emerson S.U. 1998a. Experimental infection of pigs with the newly identified swine hepatitis E virus (swine HEV), but not with human strains of HEV. *Arch. Virol.* 143:1405-1415.
- Meng X.J., Halbur P.G., Shapiro M.S., Govindarajan S., Bruna J.D., Mushahwar I.K., Purcell R.H. & Emerson S.U. 1998b. Genetic and experimental evidence for cross-species infection by swine hepatitis E virus. *J. Virol.* 72:9714-9721.
- Meng X.J. 2010. Hepatitis E virus: Animal reservoirs and zoonotic risk. *Vet. Microbiol.* 140:256-265.
- Schlosser J., Eiden M., Vina-Rodriguez A., Fast C., Dremsek P., Lange E., Ulrich R.G. & Groschup M.H. 2014. Natural and experimental hepatitis E virus genotype 3 - infection in European wild boar is transmissible to domestic pigs. *Vet. Res.* 45:121.
- Smith D.B., Simmonds P., International Committee on Taxonomy of Viruses Hepeviridae Study Group, Jameel S., Emerson S.U., Harrison T.J., Meng X.J., Okamoto H., Van der Poel W.H. & Purdy M.A. 2014. Consensus proposals for classification of the family *Hepeviridae*. *J. Gen. Virol.* 95:2223-2232.
- Wang Y., Ling R., Erker J.C., Zhang H., Li H., Desai S., Mushahwar I.K. & Harrison T.J. 1999. A divergent genotype of hepatitis E virus in Chinese patients with acute hepatitis. *J. Gen. Virol.* 80:169-177.
- Yu C., Boon D., McDonald S.L., Myers T.G., Tomioka K., Nguyen H., Engle R.E., Govindarajan S., Emerson S.U. & Purcell R.H. 2010. Pathogenesis of hepatitis E virus and hepatitis C virus in chimpanzees: similarities and differences. *J. Virol.* 84:11264-11278.