

## Epidemiological, clinical and pathological features of canine parvovirus 2c infection in dogs from southern Brazil<sup>1</sup>

Pablo S.B. de Oliveira<sup>2</sup>, Juliana F. Cargnelutti<sup>2</sup>, Eduardo K. Masuda<sup>3</sup>, Rafael A. Figuera<sup>4</sup>, Glaucia D. Kommers<sup>4</sup>, Marcia C. da Silva<sup>4</sup>, Rudi Weiblen<sup>2</sup> and Eduardo F. Flores<sup>2\*</sup>

**ABSTRACT.**- De Oliveira P.S.B., Cargnelutti J.F., Masuda E.K., Figuera R.A., Kommers G.D., Silva M.C., Weiblen R. & Flores E.F. 2018. **Epidemiological, clinical and pathological features of canine parvovirus 2c infection in dogs from southern Brazil.** *Pesquisa Veterinária Brasileira* 38(1):113-118. Setor de Virologia, Departamento de Medicina Veterinária Preventiva, Centro de Ciências Rurais, Universidade Federal de Santa Maria, Av. Roraima 1000, 63A, Santa Maria, RS 97105-900, Brazil. E-mail: [eduardofurtadoflores@gmail.com](mailto:eduardofurtadoflores@gmail.com)

Canine parvovirus type 2c (CPV-2c) emerged in Europe in the early 2000's and rapidly spread out worldwide. Clinical and molecular data have demonstrated its circulation in Brazilian dogs, yet detailed descriptions of cases are still lacking. This article describes the epidemiological, clinical and pathological features of 24 cases of CPV-2c-associated disease in dogs submitted to veterinary clinics and laboratory diagnosis in southern Brazil (2014-2016). Most affected dogs presented signs/lesions suggestive of parvovirus enteritis: diarrhea, vomiting, hyperemia and hemorrhage of the serous membrane of the small intestine, diffuse segmental granulation, atrophy of the villi, necrosis and fusion of crypts, squamous metaplasia and epithelial syncytia. A number of cases presented features divergent from the classical presentations, including a wide variation in the color of feces (reddish and/or yellowish, light-brownish, orange-brown and brownish), involvement of adults (4/24) and vaccinated dogs (12/24), extensive involvement of the small intestine (8/20) and the presence of pulmonary edema (7/24) and convulsions (3/24). Feces and intestinal fragments submitted to PCR for the CPV-2 VP2 gene and to virus isolation in cell culture yielded positive results in 100% and 58.3% (14/24) of the cases, respectively. Nucleotide sequencing revealed a high nucleotide identity in VP2 (99.4 to 100%) and a consistent mutation at amino acid 426 (asparagine to glutamic acid), considered a signature of CPV-2c. These results confirm the involvement of CPV-2c in the described cases and demonstrate the importance of CPV-2c infection among Brazilian dogs, calling attention of veterinarians to correctly diagnose the disease, mainly considering the frequent atypical presentations.

INDEX TERMS: Epidemiology, clinics, pathology, canine parvovirus 2c, dogs, CPV-2c, *Parvoviridae*, gastrointestinal disease, new variant.

**RESUMO.**- [Aspectos epidemiológicos, clínicos e patológicos da infecção pelo parvovírus canino 2c em cães do Sul do Brasil.] O parvovírus canino tipo 2c (CPV-2c) surgiu na Europa no início do ano 2000 e rapidamente se espalhou

pelas populações de cães ao redor do mundo. Dados clínicos e moleculares demonstraram a sua circulação em cães brasileiros, porém descrições detalhadas desses casos ainda são escassas. Este artigo descreve os aspectos epidemiológicos, clínicos e patológicos de 24 casos de doença gastroentérica associada com a infecção pelo CPV-2c em cães atendidos em clínicas veterinárias e submetidos ao diagnóstico laboratorial no Sul do Brasil (2014-2016). A maioria dos cães afetados apresentaram sinais e/ou lesões sugestivas de enterite por parvovírus: diarreia, vômitos, hiperemia e hemorragia na membrana serosa do intestino delgado, granulação segmentar difusa, atrofia das vilosidades, necrose e fusão de criptas, metaplasia escamosa e sincícios epiteliais. Alguns casos apresentaram características divergentes das apresen-

<sup>1</sup> Received on November 7, 2016.

Accepted for publication on March 26, 2017.

<sup>2</sup> Setor de Virologia, Departamento de Medicina Veterinária Preventiva, Centro de Ciências Rurais, Universidade Federal de Santa Maria (UFSM), Av. Roraima, 1000, 63A, Santa Maria, RS 97105-900, Brazil. \*Corresponding author: [eduardofurtadoflores@gmail.com](mailto:eduardofurtadoflores@gmail.com)

<sup>3</sup> Axys Análises Laboratório Veterinário e Consultoria, Rua Pedro Chaves Barcelos 475, Porto Alegre, RS 90450-010, Brazil.

<sup>4</sup> Laboratório de Patologia Veterinária, Departamento de Patologia, Centro de Ciências da Saúde, UFSM, Av. Roraima 1000, 79B, Santa Maria, RS 97105-900.

tações clássicas, incluindo uma grande variação na cor das fezes (avermelhada e/ou amarelada, marrom-claro, marrom-alaranjada ou amarronzada), a participação dos adultos (4/24) e cães vacinados (12/24), um amplo envolvimento do intestino delgado (8/20), a presença de edema pulmonar (7/24) e convulsões (3/24). As fezes e fragmentos intestinais foram submetidos ao teste de PCR para o gene VP2 do CPV-2, e ao isolamento do vírus em cultura de células produziram resultados positivos em 100% e 58,3% (14/24) dos casos, respectivamente. O sequenciamento dos nucleótidos revelou uma alta identidade de nucleótidos na VP2 (99,4-100%) e uma mutação no aminoácido 426 (asparagina para ácido glutâmico), considerada uma assinatura de CPV-2c. Estes resultados confirmam o envolvimento do CPV-2c nos casos descritos e demonstra a importância da infecção pelo CPV-2c entre os cães do Brasil, chamando a atenção de veterinários para diagnosticar corretamente a doença, principalmente considerando-se as apresentações atípicas frequentes.

**TERMOS DE INDEXAÇÃO:** Epidemiologia, clínica, patologia, parvovirus canino 2c, cães, CPV-2c, *Parvoviridae*, doença gastrointestinal, nova variante.

## INTRODUCTION

Canine parvovirus type 2 (CPV-2) is a small (27-30nm) non-enveloped, single stranded DNA virus belonging to the family *Parvoviridae*, closely related to feline panleucopenia virus (FPLV) (ICTV 2016). CPV infection is highly contagious and frequently courses with severe gastroenteric disease and myocarditis in neonatal puppies, and is an important cause of death in young dogs (Appel et al. 1979, Carmichael & Binn 1981, Decaro et al. 2007).

Strong genetic and experimental evidence support that CPV-2 emerged from FPLV in the late 70's, through six or seven mutations in amino acids of the capsid protein (VP2), following by adaptation and evolution in the new host (Appel et al. 1979, Truyen 1999, Decaro et al. 2007). In the years following its emergence, CPV-2 spread out worldwide, frequently associated with a highly fatal hemorrhagic gastroenteric disease affecting mainly young dogs (younger than 1 year-old). Promptly, effective CPV-2 vaccines were developed and vaccination became usual worldwide (Pollock & Carmichael 1982, 1983). At least two new antigenic variants (CPV-2a and 2b) emerged from the parental virus by four amino acid mutations in VP2 in relation to original virus (2 to 2a) and by two changes in the new virus (2a to 2b) (Ikeda 2002, Martella et al. 2004, Truyen 2006), gradually replacing the original virus in dog populations (Truyen 2006).

In 2001, a new CPV-2 subtype (2c) was identified in Italy, causing severe hemorrhagic diarrhea in dogs (Buonavoglia et al. 2001). This variant was subsequently shown to affect adult and immunized dogs, and also cats (Buonavoglia et al. 2001, Decaro & Buonavoglia 2012, Miranda et al. 2014), quickly spread out and became established in dog populations throughout the world (Cotmore & Tattersall 1996, Buonavoglia et al. 2001, Pérez et al. 2007, Streck et al. 2009, Nandi & Kumar 2010, Parthiban et al. 2010). Up to the present, the CPV-2c variant has been detected in high frequencies in many countries. Epidemiologic survey of fecal samples of dogs from Western European showed that the original CPV-

2 was replaced by its variants, being the CPV-2c the most prevalent in Italy and Germany and at high rates in Spain and France (Decaro & Buonavoglia 2012). In Ecuador, CPV-2c was the most prevalent variant detected (54.7%) in rectal swabs of puppies (Aldaz et al. 2013). Molecular epidemiology in stool samples of dogs with diarrhea from China showed CPV-2c in 14.74% of the samples (Geng et al. 2015). To determine the CPV-2c circulation in USA, stool samples of vaccinated and unvaccinated dogs from 16 states were analyzed, showing that 25.92% of the samples contained CPV-2c (Hong et al. 2007). These data indicate the worldwide distribution of CPV-2c and call attention for its prompt identification, correct diagnosis and control measures.

The CPV-2c genome holds at least two mutations in the VP2 gene that distinguish it from CPV-2a and CPV-2b (Ikeda 2002, Martella et al. 2004, Truyen 2006). One of these mutations, amino acid position 426: 2a -asparagine, 2b - aspartic acid, 2c - glutamic acid affects an epitope involved in binding to cellular receptors, thereby potentially influencing pathogenesis and neutralization by antibodies (Parrish 1999). The CPV-2c emergence caused a great concern among breeders, dog owners and veterinarians, due to its rapid spread and the uncertainty about the cross-protection conferred by CPV-2 vaccines (Truyen 2006, Hernández-Blanco & Catala-López 2015).

In South America, CPV-2c was first identified in 2006 in feces from symptomatic dogs in Uruguay (Pérez et al. 2007). Subsequently, this variant was detected in neighbor countries, such as Brazil, Argentina, and others, following by genetic characterization of VP2 mutations (Pérez et al. 2007, Calderon et al. 2009, Streck et al. 2009, Castro et al. 2010, Pinto et al. 2012, Fontana et al. 2013). Nonetheless, clinical and pathological descriptions of these cases are rare and generally rather incomplete. Thus, the objective of this article is to provide an epidemiological, clinical and pathological description of 24 cases of disease associated with CPV-2c infection in dogs in southern Brazil.

## MATERIALS AND METHODS

**Samples.** Fecal samples or intestine segments of 24 dogs presenting gastrointestinal disease were included in the study. Only cases in which the epidemiological or clinical and pathological features were somehow divergent from the classical presentation of parvovirus enteritis were included (Table 1), as a wide variation in the color of feces, involvement of adults and vaccinated dogs, extensive involvement of the small intestine and the presence of pulmonary edema and convulsions. The samples were obtained from veterinary clinics and pathology laboratories located in Santa Maria and Porto Alegre cities, Rio Grande do Sul State (RS), southern Brazil (2014-2016), and maintained at -20°C. In the virology laboratory, the samples were submitted to virus isolation and PCR for CPV-2 VP2 sequences, followed by nucleotide sequencing of the amplicons.

**Virus isolation.** Virus isolation was performed in Crandell Rees feline kidney (CrFK) cells. For this, approximately 1g of feces or intestine segments were macerated using sterile sand, resuspended in minimal essential medium (MEM) at 1:10 (weight/volume) and clarified by centrifugation (1300 xg, 10min) at 4°C. The supernatant (250 µl) was inoculated into CrFK cell monolayers grown in 12-well plates. Inoculated cells were maintained in 5% of CO<sub>2</sub> atmosphere at 37°C during 96h, and daily monitored for cytopathic effect (cpe). Samples were considered negative for virus after three passages of

four days each without production of cpe. Virus identification was performed by a PCR targeting the CPV-2 VP2 gene, in DNA extracted from cells presenting cpe or directly from clinical samples.

**PCR and variant determination.** Total DNA extracted from inoculated cell cultures, macerated feces or intestine fragments was submitted to a PCR assay targeting the FPLV/CPV-2 VP2 gene (Buonavoglia et al. 2001). DNA extraction of 500µl of each sample was performed using phenol and chloroform protocol. The primers used were: 555\_for 5'-CAGGAAGATATCCAGAAGGA-3' and 555\_rev 5'-GGTGCTAGTTGATATGTAATAACA-3 that amplify a product of 583bp (Buonavoglia et al. 2001). PCR reactions were performed in 100µl volume, using 4µl of template DNA (100 to 200 ng of total DNA), 0.5µM of each primer, 2.5mM MgCl<sub>2</sub>, 10mM of dNTPs, 1 × reaction buffer and 4 units of Taq polymerase (Invitrogen®). PCR conditions were: initial denaturation (94°C for 2 min), followed by 30 cycles of 94°C/45s; 50°C/45s for primer annealing and 72°C/45s for primer extension; and a final extension of 7 min at 72°C. PCR products were resolved in a 1.5% agarose gel stained by Gel Red® and visualized under UV light after electrophoresis (60V, 40min). The PCR product was purified using PureLink Quick Gel Extraction kit® (Thermo Scientific®) and submitted to nucleotide sequencing in quadruplicates in an automatic sequencer (BigDye reagent, ABI-PRISM 3100 Genetic Analyzer®). The obtained sequences were analyzed by Staden program (Staden 1996) for consensus sequences achievement, translated and aligned with reference sequences of each variant obtained from GenBank (CPV-2a: accession number KM386823, CPV-2b: JF414817, CPV-2c: JF414826) using the program BioEdit Sequence Alignment Editor Software suite, version 7.0.5.3 (Hall 1999).

The identification of the CPV-2 variant was performing through analyzes of the amino acid residue at position 426, as follows: asparagine determines subtype 2a; aspartic acid determines 2b; and glutamic acid determines 2c (Buonavoglia et al. 2001).

**Pathological analysis.** Most dogs presenting gastroenteritis were submitted to a full necropsy (n=20). Tissue fragments were fixed in 10% buffered formalin for 24 to 48h. After tissue processing, paraffin-embedded samples were cut in 3-µm-thick sections and stained with hematoxylin and eosin for histological examination. Sections of the small intestine were also collected in sterile recipients and maintained at -20°C for virus isolation and PCR.

## RESULTS AND DISCUSSION

The epidemiological and clinical data of the described cases are summarized in Table 1. All reported cases presented gastrointestinal disease, in which diarrhea was the most frequent finding. In general, diarrhea ranged from watery to pastous and was, in some cases, hemorrhagic. Feces were often reddish and/or yellowish, but occasionally light-brownish, orange-brown and brownish (Table 1 and 2). Other clinical signs observed were vomiting, inappetence/anorexia and prostration/apathy. Leukopenia was reported in seven dogs. Three dogs had neurological signs, such as convulsion and vocalization (SV241/15, SV406/15 and SV678/15).

The disease affected dogs of different ages, yet most animals were younger than one year (17/24) and four were

**Table 1. Epidemiological and clinical findings of CPV-2c-associated disease in dogs from southern Brazil**

Identification	Breed	Age	Vaccination status	Clinical signs						Observations
				Inappetence/ anorexia	Emesis	Diarrhea	Leuco- penia	Prostration/ apathy	Death	
239/15	Lhasa Apso	4 months	Complete protocol		+	+	+		+	
240/15	Pug	ni	ni	+		+	+	+	+	
241/15	Akita	2 months	1 dose	+	+	+		+	+	Convulsions
242/15	Mongrel	2 months	Not vaccinated	+		+	+		+	
243/15	Shih Tzu	4 years	Complete protocol	+	+	+	+	+	+	
247/15	Mongrel	3 months	Complete protocol		+	+		+	+	Necropsy not performed
248/15	Border Collie	2 years	Complete protocol			+			+	
251/15	Yorkshire	5 months	Complete protocol			+	+		+	
253/15	Shih Tzu	45 days	1 dose			+			+	
406/15	Bulldog	2 months	ni		+	+		+	+	Bloody diarrhea, convulsions, vocalization
407/15	Bulldog	3 months	2 doses			+			+	Watery diarrhea
600/15	Mongrel	6 months	ni		+	+	+			Necropsy not performed
601/15	Rottweiler	7 months	ni			+				Greenish diarrhea; necropsy not performed
615/15	German Spitz	4 months	2 doses		+	+			+	Brownish-orange diarrhea
636/15	Italian Volpino	2 months	2 doses		+	+		+	+	Intestinal infection during 30 days; antibiotic and antiparasitary therapy
638/15	Mongrel	1 month	1 dose		+	+		+	+	-
678/15	Poodle	ni	ni			+			+	Convulsions
679/15	Pug	2 years	ni		+	+	+		+	Yellowish diarrhea
731/15	Mongrel	3 months	Not vaccinated	+	+	+		+	+	Antiparasitary therapy
18/16	Dachshund	6 months	Not vaccinated		+	+			+	Bloody diarrhea
20/16	Dachshund	3 months	Not vaccinated	+	+	+			+	-
32/16	Yorkshire	50 days	Not vaccinated		+	+			+	-
74/16	Mongrel	2 years	ni			+				Criptosporidium sp. infection; necropsy not performed
129/16	Poodle	3 months	1 dose	+	+	+				Severe anemia

+ Presence of reported clinical signs, ni = not informed.

**Table 2. Pathological findings in dogs naturally infected by canine parvovirus type 2c**

ID	Distribution of lesions	Staining of intestinal content	Other systems/observations
239/15	Jejunum and ileum	Brownish	
240/15	Jejunum	Orange-brownish	Pulmonary edema
241/15	ni	Yellowish	Pulmonary edema
242/15	ni	Slightly reddish	Necrotizing hepatitis, enlarged and edematous tonsils
243/15	Jejunum	Yellowish	Pulmonary edema
248/15	Jejunum	Reddish	Pulmonary congestion and edema
251/15	Whole small intestine	Yellowish to reddish	
253/15	Jejunum	Reddish	Mild intestinal adhesion
406/15	Jejunum	Reddish	Pulmonary congestion and edema
407/15	ni	Yellowish	
615/15	Whole small intestine	Reddish	Necrosis of lymphoid nodules
636/15	ni	ni	Suppurative enteritis and cryptitis associated with coccidia infection; erosive and ulcerative gastritis
638/15	ni	Light-brownish	Suspect of intestinal parasitosis
678/15	Duodenum and jejunum	Light-brownish	
679/15	Whole small intestine	Yellowish to reddish	Pulmonary congestion and edema; submitted to caesarean 15 days before the death
731/15	Whole small intestine	Yellowish to reddish	Depletion of Payer's patches; antiparasitary treatment
18/16	Whole small intestine	Light yellowish	Reddish and enlarged mesenteric lymph node. Pulmonary edema. Hemorrhage in gastric serous membrane
20/16	Whole small intestine	ni	Intestinal mucosa was yellowish and recovered by fibrin; depletion of Payer's patches; parasitary infection ( <i>Toxocara canis</i> )
32/16	ni	Light yellow	
129/16	Jejunum	Brownish	Anemia, enlarged mesenteric lymph nodes, moderate lymphoid hyperplasia, depletion of Payer's patches

ni = not informed.

older than two years old (Table 1). Interestingly, two of the adult animals had a complete vaccination protocol with polyvalent vaccines; the other ten had received at least one vaccine dose (Table 1).

Most dogs included in this study evolved to death (22/24). At necropsy, the most frequent gross lesions were hyperemia and hemorrhage of the serous membrane of the small intestine, diffuse or segmental granulation of the serosa, granulation and atrophy of the mucosa (Fig.1A). Some dogs had extensive lesions covering all segments of the small intestine (Fig.1B). The color of the intestinal content ranged from yellowish to reddish or brownish (Fig.1C). Pulmonary edema was also a frequent gross finding (7/20).

Microscopically, necrosis and fusion of crypts with collapse of the lamina propria, villous atrophy, squamous metaplasia and epithelial syncytia in crypts were observed in the affected dogs. The intensity and extension of the lesions showed no evident variation among dogs. Some dogs (n=3) had fibrinous plaques (Fig.1D) with bacteria aggregates in the small intestine (Table 2).

Lesions were also observed in other organic systems. Pulmonary congestion, alveolar edema and moderate mixed inflammatory infiltrate in lungs were frequently observed (7/20) (Table 2). Tonsils were enlarged and edematous. Necrosis lymphoid and depletion of Payer's patches were also observed. One dog had necrotizing hepatitis. No microscopic lesions were observed in the brains, despite the fact that three dogs had convulsions.

Stool samples and intestinal segments collected from sick dogs were submitted to virus isolation in CrFK cells. Virus isolation was achieved in 14 (58.3%) out of 24 cases. Typical CPV-2 cytopathology was initially observed by 24-48 post-inoculation (pi) in cell monolayers and reached 90 to 100% of cpe until 96h pi, or after two or three passages

in new cells. In all cases, virus identification was confirmed by PCR.

Amplification of CPV-2 sequences was either performed directly from feces/intestine segments or from viruses isolated in cell culture. After amplification, the amplicons were submitted to nucleotide sequencing. All analyzed samples were positive for VP2 sequences, yielding 583bp products, which were purified and submitted to nucleotide sequencing.

The nucleotide sequencing revealed an overall high amino acid identity (in general, 100%) with CPV-2c and lower identities with CPV2a (until 98.8%) and CPV2b (until 99.4%) sequences deposited in Genbank. The analysis of amino acid sequences of the VP2 segment revealed that all 24 samples/viruses presented a glutamic acid at residue 426. According to previous studies (Buonavoglia et al. 2001), the glutamic acid at position 426 represents a signature of variants belonging to the CPV-2c genotype.

Although diarrhea was the main clinical sign presented by affected dogs – a hallmark of parvovirus enteritis – few animals presented hemorrhagic diarrhea, a typical manifestation of CPV-2a and 2b infected dogs (Greene & Decaro 2012). The affected dogs presented watery to pastous diarrhea, and the feces were often reddish and/or yellowish, but occasionally light-brownish, orange-brown and brownish. Similarly, hemorrhagic diarrhea was not observed among dogs naturally infected with CPV-2c in Italy (Decaro et al. 2005). It should be mentioned that the atypical fecal color in many cases reported herein may induce clinicians to consider other agents like *Giardia* sp. or *Cryptosporidium* sp.

Another interesting finding was the involvement of CPV-2c with severe disease in adults. Four dogs were older than two years, including two with a complete vaccination protocol. In general, CPV-2a and 2b-associated disease oc-



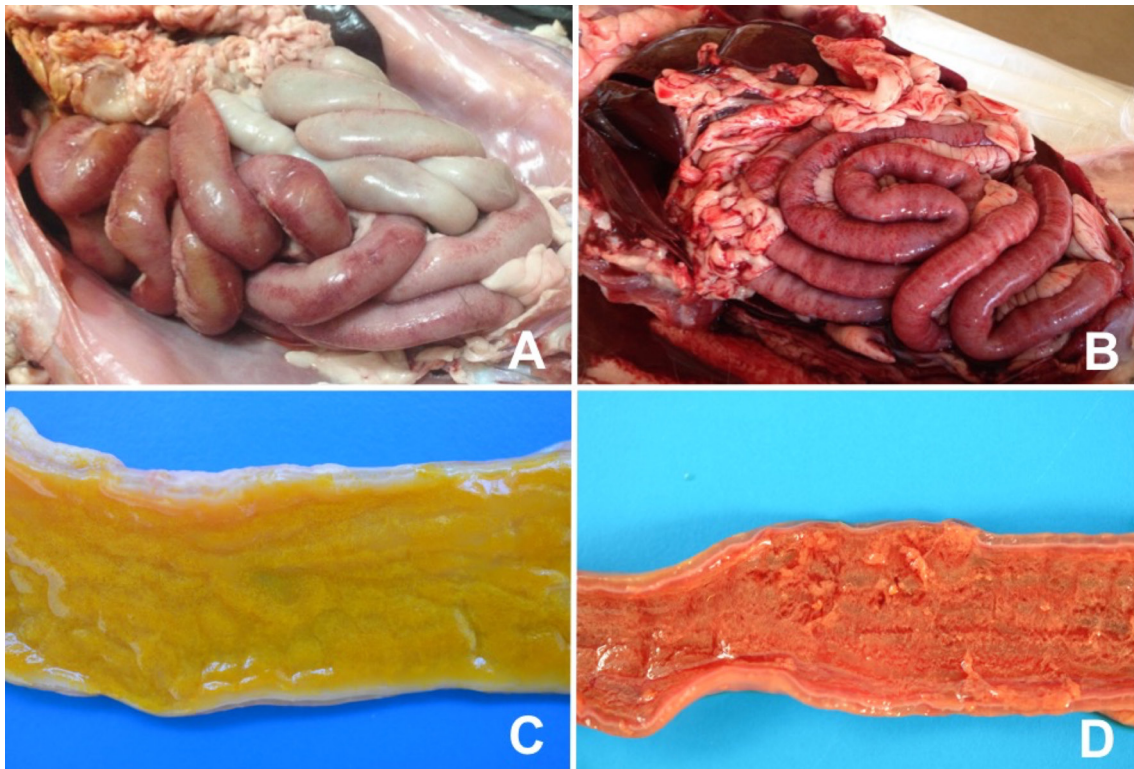


Fig.1. Macroscopic lesions observed in small intestine of dogs infected with canine parvovirus type 2c. (A) Segmental hyperemia of jejunum (lesion observed in most dogs). (B) Diffuse lesions covering all segments of the small intestine were observed in some dogs. (C) Yellowish and translucent intestinal content observed in most dogs, diverging from the classical hemorrhagic enteritis. (D) Some dogs had fibrinous plaques in the intestinal lumen.

occurs mainly in puppies younger than one year-old, after maternal antibody waning and before completion of the immunization protocol (Lamm & Rezabek 2008, Decaro & Buonavoglia 2012). The high rate of mitosis in the target crypt cells, which offers an optimal environment for parvovirus replication probably favors the high rate of CPV-2 replication in young dogs (Cotmore & Tattersall 1996). On the other hand, adult animals may not offer such conditions and, in addition, most may have been exposed and/or vaccinated previously (Prittie 2004, Decaro et al. 2007, Decaro & Buonavoglia 2012, Pinto et al. 2012). Thus, it is tempting to speculate that the surprising high incidence of CPV-2c in adult animals in the present report might be partially related to lack of protective immunity, either by non-protective vaccination (that contain only CPV-2a or 2b antigens) or by natural exposure to other CPV types.

Some animals (n=7) developed severe leukopenia. Massive virus replication in leukocytes frequently leads to cell lysis and consequent acute lymphopenia (Pollock & Carmichael 1982). Other clinical signs observed in infected animals were vomiting, inappetence/anorexia and prostration/apathy. These clinical signs are common in infected CPV-2 dogs, regardless the virus variant (Decaro & Buonavoglia 2012, Greene & Decaro 2012).

An important pathological finding in CPV-2c infected dogs was the wide extension of lesions in the small intestine. Most animals (8/20) submitted to necropsy, presented lesions in two sections (duodenum and jejunum; or jejunum and ileum) or in all extension of the small intestine. These find-

ings somehow differ from most cases of classical parvovirus enteritis by CPV-2a and CPV-2-b, when a common finding is segmental enteritis (Lamm & Rezabek 2008). In general, necrosis and fusion of the crypts, villous atrophy, squamous metaplasia and the presence of epithelial syncytia were observed in crypts of all necropsied animals. These lesions occur due to extensive virus replication in the cryptic cells, and the consequent attempt of intestinal epithelium regeneration. Necrosis crypt and villus atrophy combined with neutropenia due to bone marrow aplasia favors bacterial invasion and septicemia, sequentially, and may lead to dehydration, endotoxic and/or hypovolemic shock (Zachary 2012).

Some affected animals developed severe systemic disease accompanied by respiratory distress, pulmonary congestion and edema, alveolar and bronchiolar hemorrhage and, occasionally, convulsions. In fact, some owners described convulsions and respiratory distress, as one of the main complaints, along with diarrhea. These events may be correlated with hypovolemic, endotoxic and septicemic shock (Prittie 2004, Goddard & Leisewitz 2010), yet they seem not exclusive of CPV-2c infected dogs (Nandi & Kumar 2010). These signs have been also observed in the cardiac syndrome or myocarditis associated with parvovirus infection of puppies (Carpenter et al. 1980), but are rare in dogs presenting hemorrhagic gastroenteric disease.

An important pathological lesion observed in parvovirus-infected dogs is the depletion of Peyer's patches, reflecting an initial virus replication in lymphoid tissues with subsequent spread to the cryptic epithelium (Robinson et

al. 1980). This lesion was observed in some dogs infected by CPV-2c, associated (or not) with enlargement and edema of lymphoid organs.

CPV-2c was detected in feces and/or intestinal segments of all affected animals by virus isolation and/or PCR and nucleotide sequencing. The variant CPV-2c is widespread among dog populations, including Brazil and other South American countries. Thus, a detailed description of epidemiology, clinical, pathological and virological aspects of naturally CPV-2c infected dogs may help clinicians to recognize the disease, mainly due to its frequent non-classical clinical presentation and involvement of adult, vaccinated animals. This report may also call attention for prevalent circulation of the variant in the country and, therefore, for the urgent need for inclusion of CPV-2c strains in vaccine formulations.

**Conflict of interest statement** - The author(s) declared no potential conflicts of interest with respect to the research, authorship, and/or publication of this article.

**Funding**- J.F. Cargnelutti, E.F. Flores, G.D. Kommers and R. Weiblen are Conselho Nacional de Desenvolvimento Científico e Tecnológico (CNPq) research fellows.

## REFERENCES

- Aldaz J., García-Díaz J., Calleros L., Sosa K., Iraola G., Marandino A., Hernández M., Panzera Y. & Pérez R. 2013. High local genetic diversity of canine parvovirus from Ecuador. *Vet. Microbiol.* 166:214-219.
- Appel M.J.G., Scott F.W. & Carmichael L.E. 1979. Isolation and immunization studies of a canine parvo-like virus from dogs with hemorrhagic enteritis. *Vet. Res.* 105:156-159.
- Buonavoglia C., Martella V., Pratelli A., Tempesta M., Cavalli A., Buonavoglia D., Bozzo G., Elia G., Decaro N. & Carmichael L. 2001. Evidence for evolution of canine parvovirus type 2 in Italy. *J. Gen. Virol.* 82:3021-3025.
- Calderon M.G., Mattion N., Bucafusco D., Fogel F., Remorini P. & La Torre J. 2009. Molecular characterization of canine parvovirus strains in Argentina: Detection of the pathogenic variant CPV2c in vaccinated dogs. *J. Virol. Methods* 159:141-145.
- Carmichael L.E. & Binn L.N. 1981. New enteric diseases in the dog. *Adv. Vet. Sci. Comp. Med.* 25:1-37.
- Carpenter J.L., Roberts R.M., Harpster N.K. & King N.W. Jr. 1980. Intestinal and cardiopulmonary forms of parvovirus infection in a litter of pups. *J. Am. Vet. Med. Assoc.* 176:1269-1273.
- Castro T.X., Costa E.M., Leite J.P.G., Labarthe N.V. & Cubel Garcia R.C.N. 2010. Partial VP2 sequencing of canine parvovirus (CPV) strains circulating in the state of Rio de Janeiro, Brazil: detection of the new variant CPV-2c. *Braz. J. Microbiol.* 41:1093-1098.
- Cotmore S.F. & Tattersall P. 1996. Parvovirus DNA replication. In: *DNA Replication in Eukaryotic Cells*. Cold Spring Harbor Monograph Archive, 31:799-813.
- Decaro N., Desario C., Campolo M., Elia G., Martella V., Ricci D., Lorusso E. & Buonavoglia C. 2005. Clinical and virological findings in pups naturally infected by canine parvovirus type 2 Glu-426 mutant. *J. Vet. Diagn. Invest.* 17:133-138.
- Decaro N., Desario C., Addie D. D., Martella V., Vieira M. J., Elia G., Zicola A., Davis C., Thompson G., Thiry E., Truyen U. & Buonavoglia C. 2007. Molecular epidemiology of canine parvovirus, Europe. *Emerg. Infect. Dis.* 13:1222-1224.
- Decaro N. & Buonavoglia C. 2012. Canine parvovirus: a review of epidemiological and diagnostic aspects, with emphasis on type 2c. *Vet. Microbiol.* 155:1-12.
- Fontana D.S., Rocha P.R.D., Cruz R.A.S., Lopes L.L., Melo A.L.T., Silveira M.M., Aguiar D.M. & Pescador C.A. 2013. A phylogenetic study of canine parvovirus type 2c in midwestern Brazil. *Pesq. Vet. Bras.* 33:214-218.
- Geng Y., Guo D., Li C., Wang E., Wei S., Wang Z., Yao S., Zhao X., Su M., Wang X., Wang J., Wu R., Feng L. & Sun D. 2015. Co-circulation of the rare CPV-2c with unique Gln370Arg substitution, new CPV-2b with unique Thr440Ala substitution, and new CPV-2a with high prevalence and variation in heilongjiang province, Northeast China. *PLoS One.* 10:e0137288.2015.
- Greene C.E. & Decaro N. 2012. Canine viral enteritis, p.67-80. In: Greene C.E. (Ed.) *Infectious Disease of the Dog and Cat*, 4th ed. Elsevier Saunders, St Louis, Missouri.
- Goddard A. & Leisewitz A.L. 2010. Canine Parvovirus. *Vet. Clin. Small Anim.* 40:1041-1053.
- Hall T.A. 1999. BioEdit: a user-friendly biological sequence alignment editor and analysis program for Windows 95/98/NT. *Nucleic Acids Symp. Ser.* 41:95-99.
- Hernández-Blanco B. & Catala-López F. 2015. Are licensed canine parvovirus (CPV2 and CPV2b) vaccines able to elicit protection against CPV2c subtype in puppies?: a systematic review of controlled clinical trials. *Vet. Microbiol.* 180:1-9.
- Hong C., Decaro N., Desario C., Tanner P., Pardo M.C., Sanchez S., Buonavoglia C. & Saliki J.T. 2007. Occurrence of canine parvovirus type 2c in the United States. *J. Vet. Diagn. Invest.* 19:535-539.
- ICTV 2016. International Committee on Taxonomy of Viruses. Available from <<http://www.ictvonline.org/proposals/2013.001a-aaaVA.v4.Parvoviridae.pdf>> (Cited April 4, 2016).
- Ikeda Y. 2002. Feline host range of canine parvovirus: recent emergence of new antigenic types in cats. *Emerg. Infect. Dis.* 6:341-346.
- Lamm C.G. & Rezabek G.B. 2008. Parvovirus Infection in Domestic Companion Animals. *Vet. Clin. Small Anim.* 38:837-850.
- Martella V., Cavalli A., Pratelli A., Bozzo G., Camero M., Buonavoglia D., Narcisi D., Tempesta M. & Buonavoglia C. 2004. A canine parvovirus mutant is spreading in Italy. *J. Clin. Microbiol.* 42:1333-1336.
- Miranda C., Parrish C.R. & Thompson G. 2014. Canine parvovirus 2c infection in a cat with severe clinical disease. *J. Vet. Diagn. Invest.* 26:462-464.
- Nandi S. & Kumar M. 2010. Canine Parvovirus: current perspectives. *Indian J. Virol.* 21:31-44.
- Parrish C.R. 1999. Host range relationships and the evolution of canine parvovirus. *Vet. Microbiol.* 69:29-40.
- Parthiban S., Mukhopadhyay H.K., Antony P.X. & Pillai R.M. 2010. Molecular typing of canine parvovirus occurring in pondicherry by multiplex PCR and PCR-RFLP. *Indian J. Virol.* 21:86-89.
- Pérez R., Francia L., Romero V., Maya L., López I. & Hernández M. 2007. First detection of canine parvovirus type 2c in South America. *Vet. Microbiol.* 124:147-152.
- Pinto L.D., Streck A.F., Gonçalves K.R., Souza C.K., Corbellini A.O., Corbellini L.G. & Canal C.W. 2012. Typing of canine parvovirus strains circulating in Brazil between 2008 and 2010. *Virus Res.* 165:29-33.
- Prittitt J. 2004. Canine parvoviral enteritis: a review of diagnosis, management, and prevention. *J. Vet. Emerg. Crit. Care.* 14:167-176.
- Pollock R.V.H. & Carmichael L.E. 1982. Dog response to inactivated canine parvovirus and feline panleukopenia virus vaccines. *Cornell Vet.* 72:16-35.
- Pollock R.V.H. & Carmichael L.E. 1983. Use of modified live feline panleukopenia virus vaccine to immunize dogs against canine parvovirus. *Am. J. Vet. Res.* 44:169-175.
- Robinson W.F., Huxtable C.R. & Pass D.A. 1980. Canine parvoviral myocarditis: a morphological description of the natural disease. *Vet. Pathol.* 17:282-293.
- Staden R. 1996. The Staden sequence analysis package. *Mol. Biotechnol.* 5:233-241.
- Streck A.F., de Souza C.K., Gonçalves K.R., Zang L., Pinto L.D. & Canal C.W. 2009. First detection of canine parvovirus type 2c in Brazil. *Braz. J. Microbiol.* 40:465-469.
- Truyen U. 1999. Emergence and recent evolution of canine parvovirus. *Vet. Microbiol.* 69:47-50.
- Truyen U. 2006. Evolution of canine parvovirus: a need for new vaccines? *Vet. Microbiol.* 117:9-13.
- Zachary J.F. 2012. Mechanisms of microbial infections, p.147-241. In: Zachary J.F. & McGavin M.D. (Eds), *Pathological Basis of Veterinary Disease*. 5th ed. Elsevier Saunders, St Louis, Missouri.