

Portal Vein Dopplerflowmetry in healthy sheep according to age¹

Alexandra F. Belotta², Bianca P. Santarosa^{3*}, Danilo O.L. Ferreira⁴, Sílvia M.F. Carvalho⁵, Roberto C. Gonçalves³, Carlos R. Padovani⁶ and Maria J. Mamprim²

ABSTRACT. Belotta A.F., Santarosa B.P., Ferreira D.O.L., Carvalho S.M.F., Gonçalves R.C., Padovani C.R. & Mamprim M.J. 2017. **Portal Vein Dopplerflowmetry in healthy sheep according to age.** *Pesquisa Veterinária Brasileira* 37(10):1172-1176. Departamento de Clínica Veterinária, Faculdade de Medicina Veterinária e Zootecnia, Universidade Estadual Paulista Júlio de Mesquita Filho, Unesp Campus de Botucatu, Distrito de Rubião Júnior s/n, Botucatu, SP 18618-970, Brazil. E-mail: biancasantarosavet@gmail.com

Pulsed Doppler ultrasound was used to evaluate portal blood flow, portal velocity and portal congestion index in 24 healthy sheep divided into groups (lambs, yearlings and ewes), according to age. Measurements were performed at the 11th right intercostal space using ideal insonation angle and uniform insonation method. Mean values obtained in each group were compared with one-way ANOVA, followed by Tukey *post-hoc* test. Portal velocity and portal blood flow were statistically similar between the groups ($P>0.05$). Mean portal velocity were 17.75; 17.13 and 16.75; while mean portal blood flow were 26.65; 31.04 and 24.32 for lambs, yearlings and ewes, respectively. Portal congestion index was statistically distinct between the groups and values for lambs, yearlings and ewes were 0.009; 0.058 and 0.09, respectively ($P<0.01$). Statistical differences were observed in portal vein diameter, portal vein area and portal congestion index between the groups, presumably due to influence of weight and not to age.

INDEX TERMS: Portal Vein Dopplerflowmetry, Doppler, liver, portal vein, sheep, ultrasonography.

RESUMO. [Dopplerfluxometria da veia portal em ovinos hígidos de acordo com a idade.] A ultrassonografia com Doppler pulsado foi utilizado para avaliar o fluxo sanguíneo portal, velocidade portal e índice de congestão portal em 24 ovinos saudáveis divididos em grupos (cordeiros, borregos e ovelhas), de acordo com a idade. As medições foram realizadas no 11º espaço intercostal direito utilizando ângulo

de insonação ideal e método de inclusão uniforme. Os valores médios obtidos em cada grupo foram comparados com ANOVA, seguido pelo teste *post-hoc* de Tukey. A velocidade portal e o fluxo de sangue portal foram estatisticamente semelhantes entre os grupos ($P>0,05$). A velocidade portal média foram 17,75; 17,13 e 16,75; enquanto o fluxo de sangue portal médios foram 26,65; 31,04 e 24,32 para cordeiros, borregos e ovelhas, respectivamente. O índice de congestão portal foi estatisticamente diferente entre os grupos e os valores para cordeiros, novilhos e ovelhas foram 0,009; 0,058 e 0,09, respectivamente ($P<0.01$). Observaram-se diferenças estatísticas nos diâmetros da veia porta, na área da veia porta e nos índices de congestão portal entre os grupos, provavelmente devido à influência do peso e não pela idade. TERMOS DE INDEXAÇÃO: Doppler, fígado, ovinos, ultrassonografia, veia porta.

¹ Received on on March 6, 2016.

Accepted for publication on December 9, 2016.

² Departamento de Reprodução Animaç e Radiologia Veterinária, Faculdade de Medicina Veterinária e Zootecnia (FMVZ), Universidade Estadual Paulista (Unesp), Campus Botucatu, Distrito de Rubião Júnior s/n, Botucatu, SP 18618-970, Brazil.

³ Departamento de Clínica Veterinária, FMVZ-Unesp, Campus Botucatu, Distrito de Rubião Júnior s/n, Botucatu, SP18618-970. *Corresponding author: biancasantarosavet@gmail.com

⁴ Casa de Agricultura de Agudos, Coordenaria de Assistência Técnica Integral (CATI), Departamento de Agricultura e Abastecimento do Estado de São Paulo, SP, Brazil.

⁵ Universidade de Sorocaba (Uniso), Cidade Universitária, Rodovia Raposo Tavares, Km 92,5, Sorocaba, SP18023-000, Brazil.

⁶ Departamento de Bioestatística, Instituto de Bociências de Botucatu (IBB), Unesp, Campus Botucatu, Distrito de Rubião Júnior s/n, Botucatu, SP18618-970.

INTRODUCTION

Sonographic examination in sheep has been widely used in research and clinical routine, in order to improve productivity of herds (Scott & Sargison 2010). Most studies in literature, however, refer to its use as a diagnostic tool in renal assessment due to the high rates of obstructive urolithiasis

in this species (Scott 2013), for fetal sexing (Santos et al. 2007) and for estimating carcass composition (Leeds et al. 2008). A recent study provided reference data regarding sonographic appearance of the spleen in 60 healthy sheep (Floeck et al. 2013).

Some examined normal liver in sheep using conventional sonography (Acorda et al. 2009, Kandeel et al. 2009, Néspoli et al. 2009). Others, described its usefulness for detection of liver abscesses and cysts due to *Corynebacterium pseudotuberculosis* and *Echinococcus granulosus*, respectively (Guarnera et al. 2001, Lahmar et al. 2007, Scott & Sargison 2010, Hussein & Elrashidy 2014). Another study also verified ultrasonography to be specially useful in the biliary stage of sheep hepatic fascioliasis (Gonzalo-Orden et al. 2003).

Although B-mode liver sonography presents satisfactory sensitivity for the detection of focal lesions, diagnosis of diffuse parenchymal liver diseases may be inefficient due to the large overlap of sonographic signals caused by different diseases (Feeney et al. 2008).

Sheep are not only predisposed to focal hepatic lesions but also to diffuse liver diseases, due to a variety of etiologies. Fatty liver infiltration (Kandeel et al. 2009), toxic and congestive liver diseases are of great clinical relevance and lead to significant losses in sheep production (Ulvund 1990). Cobalt deficiency, vitamin E deficiency, pregnancy toxemia, toxicosis and negative energy balance are some of the causes that can lead to fatty liver in sheep (Ulvund 1990). Liver cirrhosis was reported in sheep (Kandeel et al., 2009). Furthermore, hepatic vascular anomalies, including portosystemic shunts, although infrequent in sheep, have been reported in goats (Humann-Ziehank et al. 2001). In veterinary literature, there is a single report of hepatic adenocarcinoma in a ewe (Lofstedt et al. 1988).

Diffuse hepatocellular diseases, neoplasias and vascular anomalies often lead to significant changes in liver circulation, which can be detected by means of Doppler sonography (Kantrowitz et al. 1989). Portal vein (PV), as the carrying of a high percentage of total hepatic blood supply, is the main vessel that undergoes the effects of liver lesions (Nyland & Fisher 1990).

In human beings, as well as in companion animals, Doppler modality expanded clinical apply of sonographic exams, allowing detection of liver hemodynamic changes. In sheep, on the other hand, there has been little research on liver evaluation using B-mode ultrasound (Hussein & Elrashidy 2014) and there are no reports related to normal liver hemodynamics with Doppler sonography.

The aim of this study was to obtain normality ranges for portal vein diameter (PVD), area (PVA), velocity (PMV), flow volume (PBF) and congestion index (PCI) in healthy sheep of different ages. These indexes were also compared between the groups, to assess whether they are influenced by sheep age.

MATERIALS AND METHODS

Animals. The base population comprised 24 healthy crossbred (Ile de France x White Dorper) sheep from the Veterinary Hospital, School of Veterinary Medicine and Animal Science (FMVZ, São Paulo State University (Unesp), Botucatu, São Paulo,

Brazil). The animals were allocated into three groups: lambs (7-28 days; n=8; 4 males and 4 females), yearlings (4-5 months; n=8; 8 males) and ewes (1.5-4 years; n=8; 8 females).

Lambs and ewes were maintained under semi-intensive management. Lambs grazed on pasture with creep feed and ewes were fed corn silage and commercial feed. Yearlings were confined in collective pens and were fed a commercial feed composed of 75% concentrate and 25% crushed coast-cross hay (18 - 20% crude protein and 75% total digestible nutrients). They were kept at approximately 3m² per animal.

Animals which entered the study were considered healthy based on physical examination and biochemical analysis (aspartate aminotransferase - AST, alkaline phosphatase - ALP and gamma glutamyl-transferase - GGT). Sheep were weighed during physical examination.

Blood collection. Blood samples were collected from the jugular vein by venipuncture into 4mL Serum Clot Activator tubes (BD Vacutainer®, BD Medical, Curitiba-PR, Brazil). After blood coagulation, samples were centrifuged at 3500g for 5 minutes. The plasmas were separated and transferred to Eppendorf tubes, frozen and stored at -20°C until moment of analysis.

Biochemical analysis and enzymatic activities of serum samples were measured through the use of colorimetric commercial kits (Ebram® Produtos Laboratoriais Ltda, São Paulo, SP, Brazil). Reading was carried out in a semi-automatic biochemistry analyzer Bio-2000 (Bioplus®, São Paulo, Brazil).

Pulsed Doppler sonography. Doppler measurements were performed by a single investigator. The ultrasound device was a My Lab™30 Vet Gold (Esaote Healthcare do Brasil®, São Paulo/SP, Brazil) with a 2MHz convex transducer.

Animals were held manually, in left lateral recumbency. Trichotomy was performed covering from the eighth to the twelfth right intercostal spaces and acoustic gel was used for better contact between transducer and skin.

Before Doppler examination, the transducer was positioned at the 11th right intercostal space. PVD was measured on ultrasonogram, using the electronic cursors, at cross-sectional plane, as previously proposed (Néspoli et al. 2009) (Fig.1).

PVA could be then calculated using the following formula:

$$A = \frac{(D)^2 \times \pi}{4}$$

A = area; D = diameter; π = 3.14

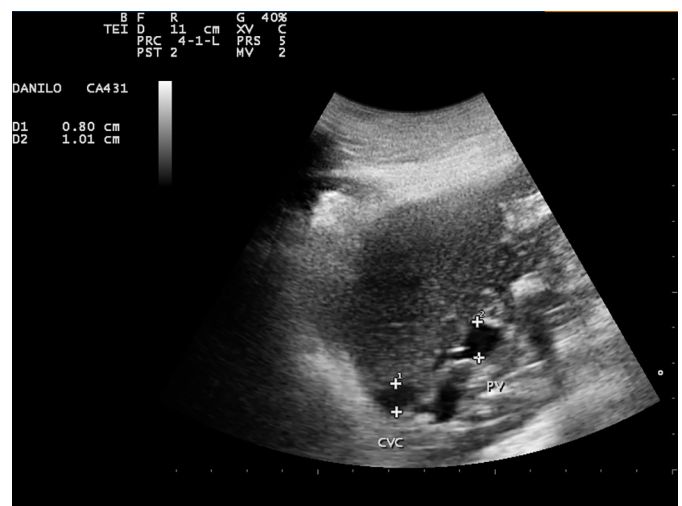


Fig.1. B-mode ultrasound image showing caudal vena cava (CVC) and portal vein (PV) at 11th right intercostal space and their diameter measurements between calipers.

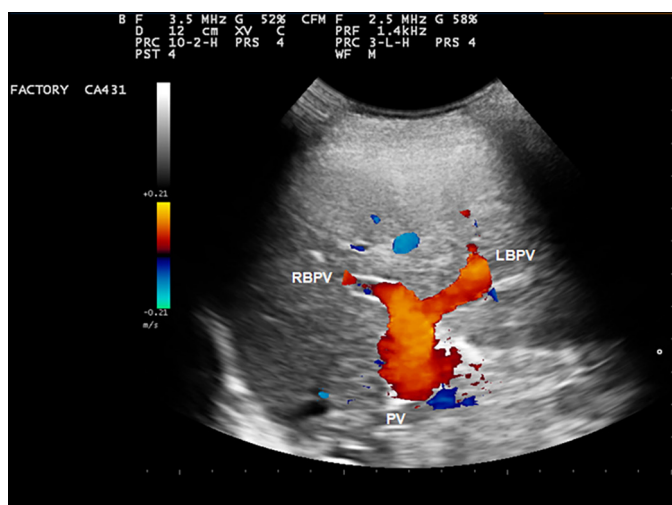


Fig.2. Color Doppler mapping showing main portal vein (PV) in a longitudinal plane, right branch of portal vein (RBPV) and left branch of portal vein (LBPV).

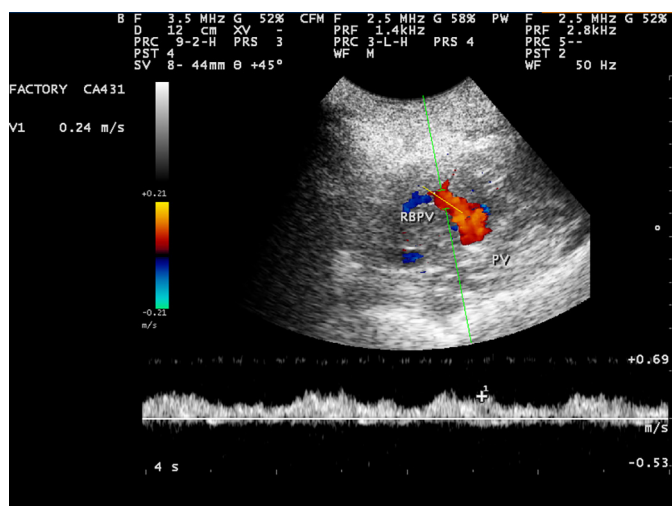


Fig.3. Pulsed Doppler image showing a pulsatile portal vein flow in the RBPV due to breathing movements. Note the insonation angle of 45°.

Using color Doppler, the transducer was manipulated to acquire a longitudinal plane of PV and an insonation angle lower than 60 degrees (Fig.2). In some cases when the ideal angle was hard to obtain, flow velocity was measured in the right branch of the PV.

Doppler sample volume was placed in the entire diameter of the vessel and overlapped the walls of PV, according to uniform insonation method (Lamb & Mahoney 1994) (Fig.3). Velocity measurement was taken three times in each animal and averaged to obtain PMV. PBF and PCI were calculated with formulae previously proposed (Kantrowitz et al. 1989, Moriyasu et al. 1986):

$$\text{PBF (mL/min/kg)} = \frac{\text{PMV (cm/s)} \times (\text{APV (cm}^2) \times 60}{\text{W (kg)}}$$

$$\text{PCI (cm x s)} = \frac{\text{APV (cm}^2)}{\text{PMV (cm/s)}}$$

Statistical analysis. Data were expressed as mean \pm standard deviation in each group. Means were compared using one-way ANOVA, followed by Tukey post hoc test to determine if any diffe-

rence was found between the groups. Statistical tests were performed for a significance level of $P < 0.05$ (Zar 2009).

Ethical aspects. This project was approved by the Ethics Committee on Animal Use (CEUA) FMVZ-Unesp, Botucatu, under the Protocol 188/2014.

RESULTS AND DISCUSSION

The mean ALP and GGT in lambs were higher than the reference ranges for sheep (Table 1) (Kaneko et al. 2008). Nevertheless, intense osteoclastic activity can increase ALP values (Ramos et al. 1994) and, in addition, colostrum ingestion led to high GGT activity in lambs (Braun et al. 2010). Some lambs who had increased ALP and GGT levels were, therefore, included in this study. Mean GGT level in yearlings was also above reference ranges. Colostral antibodies, however, should be considered, due to yearlings' age (4 months). All liver enzymes levels of ewes were within normal ranges.

Table 1. Mean (\pm standard deviation) AST, ALP and GGT of lambs, yearlings and ewes

	Groups			Reference value*
	Lambs	Yearlings	Ewes	
AST (UI/L)	67.93 \pm 21.44	109.85 \pm 44.02	104.3 \pm 21.78	60 - 280
ALP (UI/L)	565.37 \pm 182.11	224.17 \pm 66.92	130.57 \pm 46.90	68 - 387
GGT (UI/L)	138.12 \pm 85.27	70.5 \pm 14.30	37.87 \pm 11.78	20 - 52

AST = aspartate aminotransferase, ALP = alkaline phosphatase, GGT = gamma-glutamyl transferase. *Kaneko et al. (2008).

In the present study, PVD and PMV were easily measured in the 11th intercostal space of each animal by means of B-mode and pulsed Doppler sonography using manual restraint. A previous study also reported great accessibility of portal vein from 9th to 11th intercostal spaces with the animal positioned in left lateral recumbency (Kandeel et al. 2009, Néspoli et al. 2009). Some authors reported difficulties in locating liver vessels in pregnant sheep because of cranial displacement of the liver, what was not observed in the present study once none of the ewe were pregnant. PV could be differentiated from the other hepatic vessels due to its hyperechoic wall and location ventrally and laterally to the caudal vena cava, as previously reported (Kandeel et al. 2009).

In human patients, although liver biopsy is still the gold standard for definitive diagnosis, liver Doppler ultrasound parameters have been widely used to predict chronic liver diseases, liver fibrosis, fatty liver, cirrhosis and neoplasia (Gerstenmaier & Gibson 2014, Keddeas et al. 2016, Soker et al. 2016). Liver Doppler flowmetry is also considered an excellent tool in the assessment of severity of hepatic disease (Mukhopadhyay & Saha 2015). The study of hepatic vascular hemodynamics is important once changes can be detected when parenchymal liver diseases lead to changes in hepatic compliance (O'Donohue et al. 2004) and in cases of vascular anomalies. Most of the studies reported in veterinary literature, however, are limited to Doppler sonography of the liver in healthy animals (Kantrowitz et al. 1989, Lamb & Mahoney, 1994, Sartor et al. 2010b) and for assessment of portosystemic shunts (D'Anjou et al. 2004) in dogs and

cats. Therefore, there is a need to investigate the applicability of liver Doppler ultrasound in sheep. Doppler evaluation of PV and its intra-hepatic branches is based on morphology of spectral wave, flow direction and measurement of mean velocity, blood flow and congestion index (Sartor et al. 2010b). In the present study, PMV, PBF and PCI were accurately measured.

PMV was measured using uniform insonation method, which is easier to use and produces higher amplitude Doppler signal in comparison with other methods (Lamb & Mahoney 1994). Weight, portal vein diameter and area were significantly different between lambs, yearlings and ewes ($P < 0.01$) (Table 2). Higher values were determined in adult sheep, while lower values were observed in lambs, presumably due to variations in body weight. This result is in agreement with that reported by other authors (Sartor et al. 2010a), who verified significantly smaller values for PVD and PVA in small-sized dogs in comparison with medium-sized dogs.

Table 2. Mean (\pm standard deviation) W, PVD, PVA, PMV, PBF and PCI in lambs, yearlings and ewes

	Groups			P-value
	Lambs	Yearlings	Ewes	
W (kg)	6.63 \pm 1.8 ^a	32.68 \pm 1.97 ^b	60.05 \pm 2.49 ^c	$P < 0.01$
PVD (cm)	0.45 \pm 0.06 ^a	1.11 \pm 0.17 ^b	1.35 \pm 0.22 ^c	$P < 0.01$
PVA (cm ²)	0.16 \pm 0.05 ^a	0.99 \pm 0.29 ^b	1.46 \pm 0.47 ^c	$P < 0.01$
PMV (cm/s)	17.75 \pm 3.01 ^a	17.13 \pm 2.59 ^a	16.75 \pm 3.54 ^a	$P > 0.05$
PBF (mL/min/kg)	26.65 \pm 8.63 ^a	31.04 \pm 9.9 ^a	24.32 \pm 9.59 ^a	$P > 0.05$
PCI (cm x s)	0.009 \pm 0.004 ^a	0.058 \pm 0.018 ^b	0.09 \pm 0.029 ^c	$P < 0.01$

W = weight, PVD = portal vein diameter, PVA = portal vein area, PMV = portal mean velocity, PBF = portal blood flow, PCI = portal congestion index. a, b, c Means in the same row with different letters are significantly different ($P < 0.01$).

Although some authors described morphologic aspects of hepatic B-mode sonography in sheep (Néspoli et al. 2009), there are no reports on values for ovine PVD in the veterinary literature. It is important to measure PVD to calculate portal blood flow and because some diseases, including cirrhosis, can change portal vein diameter (Anda et al. 2016). In healthy calves, aged from birth to 104 days, portal vein diameter ranged from 1.4cm to 1.8cm (Braun & Kruger 2013). Considering age ranges, sheep PVDs in the present study were lower than the values obtained in calves.

There was no statistical difference in the mean values of PMV and PBF between the groups. Although there exists a difference in the arrangement of the tributaries of the portal vein in sheep in comparison with dogs and cats (Heath 1967), values obtained for portal vein velocity in the present study are close to the ones obtained in previously published studies of healthy dogs of varying sizes (Nyland & Fisher 1990). A lack of weight influence on PMV was observed in the present study, as described for dogs (Sartor et al. 2010b). Although there are no reports of the behavior of portal velocity in sheep with liver disease, in dogs portal velocity may reduce in cases of portal hypertension and cirrhosis (Sartor & Mamprim 2014), and increase in patients with intra-hepatic portosystemic shunts (D'Anjou et al. 2004).

Although the lowest PBF was observed in ewes and the highest in yearlings, no statistical difference was found between the groups. Mean flow is close to the values previously obtained in healthy medium-sized dogs (Nyland & Fisher 1990). On the other hand, the PBF of the sheep of the present study is lower than that reported by Sartor et al. (2010b). Sartor et al. (2010b) also described that body weight can influence portal blood flow in dogs (Sartor et al. 2010b), what was not observed in this study. Measurement of PBF is of great importance because portal vein contributes with two thirds of total hepatic blood supply (Kantrowitz et al. 1989) and a significant reduction in this value could, therefore, suggest an important compromise in hepatic hemodynamics.

PCI reduction was observed in human patients presenting chronic liver disease, cirrhosis and portal hypertension (Moriyasu et al. 1986). In this study, PCI was significantly different between the groups, with the lower mean value seen in lambs and the higher mean value in ewes. This presumably occurred due to lower W and, consequently, DVP, in the lambs, as described by others, for healthy dogs (Sartor et al. 2010b).

CONCLUSIONS

The present study provided data that can be used as reference ranges during sonographic evaluation of sheep at different ages in clinical routine.

Distant hemodynamic values from these described, in association to liver changes on B-mode sonography, suggest the presence of liver disease and may increase diagnostic sensitivity.

Statistical differences were observed in DVP, AVP and PCI between the groups, presumably due to influence of weight and not to age.

Acknowledgment.- The authors would like to thank the Zootechnist Francisco Manoel Nogueira Fernandes, Cabanha Chico Borborema's owner, located in São Manuel-SP, for providing all the sheep for this work.

Conflict of interest statement.- The authors have no competing interests.

REFERENCES

- Acorda J.A., Paloma J.C., Cariaso W.E. & Cabrera L.A. 2009. Comparative ultrasound features of the liver, kidneys and spleen in female sheep (*Ovis aries*) at different ages. *Philipp. J. Vet. Med.* 46:26-36.
- Anda A.C., Bordei P. & Dumitru E. 2016. The role of ultrasonography in the evaluation of portal hemodynamics in healthy adults and pathologic conditions. *ARS Med. Tomitana* 2:128-134.
- Braun J.P., Trumel C. & Bézille P. 2010. Clinical biochemistry in sheep: a selected review. *Small Rumin. Res.* 92:10-18.
- Braun U. & Krüger S. 2013. Ultrasonography of the spleen, liver, gallbladder, caudal vena cava and portal vein in healthy calves from birth to 104 days of age. *Acta Vet. Scand.* 68:1-10.
- D'Anjou M.A., Penninck D., Cornejo L. & Pibarot P. 2004. Ultrasonographic diagnosis of portosystemic shunting in dogs and cats. *Vet. Radiol. Ultrasound* 45:424-437.
- Feeney D.A., Anderson K.L., Ziegler L.E., Jessen C.R., Daubs B.M. & Hardy R.M. 2008. Statistical relevance of ultrasonographic criteria in the assessment of diffuse liver disease in dogs and cats. *Am. J. Vet. Res.* 69:212-221.

- Floeck M., Aslam S., Schaetz G., Mayr E. & Franz S. 2013. Ultrasonographic assessment of the spleen in 60 healthy sheep. *N.Z. Vet. J.* 61(3):165-167.
- Gerstenmaier J.F. & Gibson R.N. 2014. Ultrasound in chronic liver disease. *Insights Imaging* 5:441-445.
- Gonzalo-Orden M., Millán L., Álvarez M., Sánchez-Campos S., Jiménez R., González-Gallego J. & Tuñón M.J. 2003. Diagnostic imaging in sheep hepatic fascioliasis: ultrasound, computed tomography and magnetic resonance findings. *Parasitol. Res.* 90:359-364.
- Guarnera E.A., Zanzottera E.M., Pereyra H. & Franco A.J. 2001. Ultrasonographic diagnosis of ovine cystic echinococcosis. *Vet. Radiol. Ultrasound* 42:352-354.
- Heath T. 1967. Origin and distribution of portal blood in the sheep. *Am. J. Anat.* 122:95-106.
- Humann-Ziehank E., Bruegmann M. & Ganter M. 2001. Hepatoencephalopathy in a goat: clinical manifestation of an intrahepatic porto-systemic shunt. *Small Rumin. Res.* 42:157-162.
- Hussein H.A. & Elrashidy M. 2014. Evaluation of ultrasonography as a diagnostic tool for hepatic hydatid cysts in sheep. *Turk. J. Vet. Anim. Sci.* 38:409-417.
- Kandeel A.E., Omar M.S.A., Mekki N.H.M., El-Seddawy F.D. & Gomaa M. 2009. Anatomical and ultrasonographic study of the stomach and liver in sheep and goats. *Iraqi J. Vet. Sci.* 23:181-191.
- Kaneko J.J., Harvey J.W. & Bruss M.L. 2008. *Clinical Biochemistry of Domestic Animals*. 6th ed. Academic, San Diego. 916p.
- Kantrowitz B.M., Nyland T.G. & Fisher R.P. 1989. Estimation of portal blood flow using duplex real-time and pulsed Doppler ultrasound imaging in the dog. *Vet. Radiol.* 30:222-226.
- Keddeas M.W., Musa N.I., Abdelhakam S.M. & Elia R.Z. 2016. Non-invasive assessment of liver fibrosis by simple Doppler ultrasound parameters. *Int. J. Recent Scient. Res.* 7:8083-8086.
- Lahmar S., Ben Chéhida F., Pétavy A.F., Hammou A., Lahmar J., Ghannay A., Gharbi H.A. & Sarciron M.E. 2007. Ultrasonographic screening for cystic echinococcosis in sheep in Tunisia. *Vet. Parasitol.* 143:42-49.
- Lamb C.R. & Mahoney P.N. 1994. Comparison of three methods for calculating portal blood flow velocity in dogs using duplex-Doppler ultrasonography. *Vet. Radiol. Ultrasound* 35:190-194.
- Leeds T.D., Mousel M.R., Notter D.R., Zerby H.N., Moffet C.A. & Lewis G.S. 2008. B-mode, real time ultrasound for estimating carcass measures in live sheep: accuracy of ultrasound measures and their relationships with carcass yield and value. *J. Anim. Sci.* 86:3203-3214.
- Lofstedt J., Schelling S., Stowater J. & Morris E. 1988. Antemortem diagnosis of hepatic adenocarcinoma in a ewe. *J. Am. Vet. Med. Assoc.* 193:1537-1538.
- Moriyasu F., Nishida O., Ban N., Nakamura T., Sakai M., Miyake T. & Uchino H. 1986. "Congestion index" of the portal vein. *Am. J. Roentgenol.* 46:735-739.
- Mukhopadhyay I. & Saha A. 2015. Quantitative assessment of portal vein by colour Doppler imaging in patients with various liver diseases in West Bengal and reflection of pathophysiological haemodynamics and evaluation of prognosis. *Int. J. Recent Scient. Res.* 6:5234-5236.
- Néspoli P.B., Gheller V.A., Machecha G.A.B., Araújo D.K.G., Macedo Jr G.L. & Bordin A.I. 2009. Morphologic aspects of hepatic ultrasonography in sheep. *Pesq. Vet. Bras.* 29:333-338.
- Nyland T.G. & Fisher P.E. 1990. Evaluation of experimentally induced canine hepatic cirrhosis using duplex Doppler ultrasound. *Vet. Radiol.* 189-194.
- O'Donohue J., Ng C., Catnach S., Farrant P. & Williams R. 2004. Diagnostic value of Doppler assessment of the hepatic and portal vessels and ultrasound of the spleen in liver disease. *Eur. J. Gastroenterol. Hepatol.* 16:147-155.
- Ramos J.J., Verde M.T., Marca M.C. & Fernández A. 1994. Clinical chemical values and variations in Rasa Aragonesa ewes and lambs. *Small Rumin. Res.* 13:133-139.
- Santos M.H.B., Gonzalez C.I.M., Bezerra F.Q.G., Neves J.P., Reichenbach H.D., Lima P.F. & Oliveira M.A.L. 2007. Sexing of Dorper sheep fetuses derived from natural mating and embryo transfer by ultrasonography. *Reprod. Fert. Development* 19:366-369.
- Sartor R., Mamprim M.J. & Takahira R.K. 2010a. Morphometric evaluation, by ultrasonographic exam, of the portal vein, caudal vena cava and abdominal aorta in healthy dogs of different body weights. *Arch. Vet. Sci.* 15:143-148.
- Sartor R., Mamprim M.J., Takahira R.K. & Almeida M.F. 2010b. Hemodynamic evaluation of the right portal vein in healthy dogs of different body weights. *Acta Vet. Scand.* 52:1-5.
- Sartor R. & Mamprim M.J. 2014. Hipertensão portal em cães: fisiopatologia e diagnóstico. *Vet. Zootec.* 21:215-228.
- Scott P. 2013. Transabdominal ultrasonographic examination of 26 sheep with suspected urinary tract disease (2010-2012). *J. Vet. Sci. Med. Diagn.* 2:1-5.
- Scott P.R. & Sargison N.D. 2010. Ultrasonography as an adjunct to clinical examination in sheep. *Small Rumin. Res.* 92:108-119.
- Soker G., Bahadir Ozturk A., Gulek B., Kuscu F., Bilge Dogan U. & Yilmaz C. 2016. Doppler ultrasonography helps discriminate between cirrhotic and non-cirrhotic patients with viral B and C hepatitis. *Diagn. Interv. Imaging* 97:337-343.
- Ulvund M.J. 1990. Ovine White-Liver Disease: changes in blood chemistry. *Acta Vet. Scand.* 31:277-286.
- Zar I.H. 2009. *Biostatistical Analysis*. 5th ed. Prentice-Hall. New Jersey.