

Transplacental transmission of *Neospora caninum* in naturally infected small ruminants from northeastern Brazil¹

Annelise C.B.T. Nunes², Elise M. Yamasaki³, Pomy C.P. Kim³, Renata P.B. Melo³, Müller Ribeiro-Andrade³, Wagner J.N. Porto² and Rinaldo A. Mota^{3*}

ABSTRACT- Nunes A.C.B.T., Yamasaki E.M., Kim P.C.P., Melo R.P.M., Ribeiro-Andrade M., Porto W.J.N. & Mota R.A. 2017. **Transplacental transmission of *Neospora caninum* in naturally infected small ruminants from northeastern Brazil.** *Pesquisa Veterinária Brasileira* 37(9):921-925. Laboratório de Doenças Infecto-contagiosas dos Animais Domésticos, Departamento de Medicina Veterinária, Universidade Federal Rural de Pernambuco, Rua Dom Manoel de Medeiros s/n, Dois Irmãos, Recife, PE 52171-900, Brazil. E-mail: rinaldo.mota@hotmail.com

Toxoplasma gondii and *Neospora caninum* are causative agents of abortion in sheep and goats. Thus, the present study aimed to describe the transplacental transmission of these protozoans in small ruminants of northeastern Brazil. Seventeen fetuses (6 goats and 11 sheep) from farms with history of abortion were necropsied and samples were collected from different tissues (brain, liver, lung, kidney and heart). The samples were analyzed by PCR, histopathology (HP) and immunohistochemistry (IHC) to evaluate whether *T. gondii* and/or *N. caninum* infection were the cause of abortion. None of the samples was positive for *T. gondii* according to PCR and IHC results. Some brain, liver, lung, kidney and heart samples of goat fetuses were positive for *N. caninum* by PCR. In the histopathology, mild mononuclear infiltration and necrosis with calcification were observed in the liver and brain of one goat fetus, respectively, that also was positive for *N. caninum* by PCR and IHC. The results confirmed vertical transmission of *N. caninum* in naturally infected goats of northeastern, Brazil.

INDEX TERMS: *Neospora caninum*, neosporosis, transplacental transmission, abortion, goats, sheep.

RESUMO.- [Transmissão transplacentária de *Neospora caninum* em pequenos ruminantes infectados naturalmente do Nordeste do Brasil.] *Toxoplasma gondii* e *Neospora caninum* são reconhecidos como protozoário causadores de aborto em ovinos e caprinos. Desta forma, objetivou-se descrever a transmissão transplacentária desses agentes em pequenos ruminantes na região Nordeste do Brasil. Foram examinados seis fetos caprinos e onze fetos ovinos, totalizando 78 amostras de diferentes tecidos (cérebro, fígado, pulmão, rim e coração) provenientes de propriedades rurais com histórico de aborto. As amostras foram analisadas por Reação em Cadeia da Polimerase (PCR),

Histopatologia (HP) e Imunohistoquímica (IHQ), com a finalidade de associar o abortamento a *T. gondii* e/ou *N. caninum*. Nenhuma amostra foi positiva na PCR e IHQ para *T. gondii*. Algumas amostras de cérebro, fígado, pulmão, rim e coração de fetos de caprinos e ovinos foram positivas na PCR para *N. caninum*. Na histopatologia foi observado leve infiltrado mononuclear no fígado e necrose com calcificação no SNC de um caprino, associada à imunomarcagem positiva para *N. caninum* na IHQ e PCR positiva. Os resultados confirmam a transmissão vertical de *N. caninum* em caprinos naturalmente infectados na região nordeste do Brasil.

TERMOS DE INDEXAÇÃO: *Neospora caninum*, neosporose, transmissão transplacentária, aborto, caprinos, ovinos.

¹ Received on October 3, 2015.

Accepted for publication on November 26, 2016.

² Unidade Educacional Viçosa, Universidade Federal de Alagoas, Campus Arapiraca, Av. Manoel Severino Barbosa s/n, Bom Sucesso Viçosa, AL 57309-005, Brazil.

³ Laboratório de Doenças Infecto-contagiosas dos Animais Domésticos, Departamento de Medicina Veterinária, Universidade Federal Rural de Pernambuco, Rua Dom Manoel de Medeiros s/n, Dois Irmãos, Recife, PE 52171-900, Brazil. *Corresponding author: rinaldo.mota@hotmail.com

INTRODUCTION

Different diseases can compromise the reproductive success of small ruminants; however, studies have shown that infectious agents are the most important and the most commonly diagnosed causative agents of abortions in goats and sheep, significantly affecting the productivity indexes

(Menzies 2011, Moreno et al. 2012). Several bacterial, viral, fungal and protozoan agents are listed as causative agents of abortions (Givens & Manley 2008, Masala et al. 2007). *Toxoplasma gondii*, the etiological agent of toxoplasmosis, an important zoonosis responsible for significant economic losses in goats and sheep production system (Buxton et al. 2007, Kirkbride 1993, Moeller 2001), and *Neospora caninum*, which causes neosporosis, a major cause of reproductive failures in cattle in several countries (Dubey & Schares 2011), stand out among the protozoans that cause abortion.

According to the literature, *T. gondii* is the main causative agent of abortions in small ruminants among the protozoans (Buxton 1998, Buxton et al. 2007). The role of *N. caninum* in abortion in goats and sheep has not been fully understood yet. However, there are reports of abortion in sheep naturally infected by *N. caninum* in Japan (Kobayashi et al. 2001), Switzerland (Hässig et al. 2003), Slovakia (Spilovská et al. 2009), Spain (Moreno et al. 2012, González-Warleta et al. 2014) and New Zealand (Howe et al. 2012). There are also reports of abortion in goats naturally infected by *N. caninum* in the United States (Barr et al. 1992, Dubey et al. 1992), Costa Rica (Dubey et al. 1996), Italy (Eleni et al. 2004), Spain (Moreno et al. 2012) and Argentina (Unzaga et al. 2014). In Brazil, *N. caninum* congenital infection in goats and sheep has been described in the South, Southeast and Midwest regions, with no descriptions in the other regions of the country (Corbellini et al. 2001, Pinto et al. 2012, Varaschin et al. 2012, Mesquita et al. 2013).

The present study aimed to describe the transplacental transmission of *T. gondii* and *N. caninum* in abortion cases in goats and sheep submitted for diagnosis, in northeastern Brazil.

MATERIALS AND METHODS

Samples of fetal tissues. Seventeen fetuses (6 goats and 11 sheep fetuses) from farms located in State of Pernambuco, Brazil were evaluated in the present study. The fetuses were sent to the Laboratory of Infectious Diseases of the Federal Rural University of Pernambuco for determination of the etiological cause of abortion by farmers, during the year 2012 and 2013. All fetuses used in this study were between 2nd and 3rd pregnancy periods and were subjected to necropsy, when the presence of macroscopic lesions was evaluated and 78 samples were collected from different tissues (brain, liver, lung, kidney and heart). The samples were frozen (-80 °C) for later PCR analysis and tissue fragments were conserved in 10% buffered formalin for histological examination and immunohistochemistry.

Polymerase Chain Reaction. The DNA of the tissues samples (heart, liver, lung, kidney and brain) was extracted with the Wizard Genomic DNA Purification kit (Promega™) following the manufacturer's protocol. Specific nested PCR was performed with each sample to detect *Neospora caninum* and *Toxoplasma gondii* DNA. For *N. caninum*, a two-step nested PCR was carried out, using NP1/NP2 and NN1/NN2 as external and internal primers, respectively, following the protocol described by Buxton (1998). For *T. gondii*, a single tube nested PCR was performed using NP1/NP2 and Tg-NP1/Tg-NP2 as external and internal primers, respectively, following the protocol described by Hurtado et al. (2001). In each PCR reaction, purified tachyzoites of *N. caninum* and *T. gondii* and ultrapure water were used as positive and ne-

gative control, respectively. The PCR products were visualized on 2% Blue Green –stained agarose gels with UV transillumination and photodocumented.

Histopathology. For the histopathological analysis, different fragments of brain, liver, lung, kidney and heart were processed following the histological routine of slide preparation. Afterwards, the slides were stained with hematoxylin-eosin, coverslips were mounted with Canada balsam and the histological sections were examined in optical microscopy. Only 11 fetuses (three goat and eight sheep fetuses) had their tissues processed and analyzed by histopathology due to tissue autolysis.

The presence of lesions consistent with those caused by *T. gondii* and *N. caninum*, which are characterized by occurrence of multifocal necrotic foci and presence of non-suppurative inflammatory infiltrate, was evaluated (Moreno et al. 2012).

Immunohistochemistry. The avidin-biotin alkaline phosphatase complex method was used for the immunohistochemical study of *T. gondii*. The histological sections fixed in silane-coated slides were dewaxed, hydrated and subjected to antigen retrieval. For antigen retrieval, the slides were boiled in 10mM citrate buffer (pH 6.0), heated in a microwave for 20 min at high power and then washed with distilled water. Non-specific binding was blocked by incubation with 5% skim milk diluted in distilled water for 30 min at room temperature. Then, the slides were washed with distilled water, immersed in PBS and incubated in a moist chamber at 6°C for 16 hours with primary polyclonal anti-*T. gondii* antibody (AB-CAM) diluted 1/200 in PBS. Subsequently, the slides were washed in PBS and the LSAB kit (Labeled Streptavidin Biotin, Dako™) was used. Afterwards, the slides were washed in distilled water and the Permanent Red chromogen (Dako™) was used following the manufacturer's recommendations. Finally, the samples were counterstained with Harris hematoxylin, dehydrated, cleared in xylene and coverslips were mounted with Canada balsam.

The peroxidase technique was used for the immunohistochemical study of *N. caninum*. Histological sections (5µm) were adhered to glass slides coated with silane solution (3-aminopropyltriethoxysilane, Sigma-Aldrich™) diluted in 2% acetone. Then, the histological slides were deparaffinized in xylene, washed in alcohol and rinsed with distilled water. Afterwards, slides were treated with 3% hydrogen peroxide solution at room temperature for 30 min and then washed in distilled water. Subsequently, antigen retrieval was performed by heating the slides in 10mM citrate buffer (pH 6.0) in the microwave at high power (800W) for 20 minutes and washing them with distilled water. To minimize nonspecific binding, the slides were treated with 5% powder skim milk diluted in water for 30 minutes at room temperature and washed in distilled water. Subsequently, the fragments were incubated overnight at 6°C (in the refrigerator) with polyclonal primary antibody anti-*N. caninum* (VMRD, cat.210-70-NC) diluted 1:1000 in PBS. The next day, after the slides were washed with distilled water, the technique of streptavidin-biotin-peroxidase complex was performed using the LSAB kit. Peroxidase activity was revealed by the AEC Chromogen (Dako™) in accordance with the manufacturer's instructions. Subsequently, the slides were counterstained with Harris hematoxylin and mounted in Faramount Aqueous Mounting Media (Dako™). The slides were analyzed under an optical microscope (Olympus™ CX40). A positive control was used in all reactions.

RESULTS

From the 78 tissue samples analyzed by PCR, none was positive for *Toxoplasma gondii*. On the other hand, 14.1% (11/78) of the tissue samples were positive for *Neospora caninum* by PCR (Table 1).

Table 1. Histopathology and *Neospora caninum* PCR in tissue samples of goats and sheep fetuses, state of Pernambuco, Brazil

| Animals | HP ^a | | | | | PCR | | | | |
|----------|-----------------|------------------|----|----|----|-----|----|----|----|----|
| | Li | Br | Lu | He | Ki | Li | Br | Lu | He | Ki |
| Goat 1 | - | - | - | - | - | - | - | - | - | - |
| Goat 2 | - | - | ND | - | - | - | - | ND | - | - |
| Goat 3 | - | - | - | - | - | - | - | + | - | - |
| Goat 4 | - | - | - | - | - | - | - | - | - | - |
| Goat 5 | - | - | ND | ND | - | + | - | ND | ND | + |
| Goat 6 | + ^{b'} | + ^{b''} | ND | - | - | - | + | ND | - | - |
| Sheep 1 | - | ND | - | ND | - | + | ND | - | ND | - |
| Sheep 2 | - | - | - | ND | - | - | - | - | ND | - |
| Sheep 3 | - | - | - | - | - | - | - | - | - | + |
| Sheep 4 | - | - | - | - | - | - | - | - | - | - |
| Sheep 5 | - | - | - | - | - | - | - | - | - | - |
| Sheep 6 | - | - | - | - | - | + | - | - | + | - |
| Sheep 7 | - | - | - | - | - | - | - | - | - | - |
| Sheep 8 | - | - | - | - | - | - | - | - | + | - |
| Sheep 9 | - | - | - | - | - | - | - | - | - | - |
| Sheep 10 | - | - | - | - | - | + | - | - | - | - |
| Sheep 11 | - | - | - | - | - | + | - | - | - | - |

Li = Liver, Br = Brain, Lu = Lung, He = Heart, Ki = Kidney, ND = No data. ^a Lesions consistent with *Toxoplasma gondii* or *Neospora caninum* infection, ^{b'} Negative IHC, ^{b''} Positive IHC.

No significant macroscopic lesions were observed in any of the fetuses necropsied. In the histopathology, mild mononuclear infiltration and necrosis with calcification were observed in the liver and brain of one goat fetus, respectively. None of the sheep samples presented lesions consistent with *N. caninum* or *T. gondii* infection. It was not possible to evaluate the presence of lesions in some samples due to tissue autolysis.

The tissues that showed inflammatory infiltrate suggestive of *T. gondii* and *N. caninum* infection were evaluated by IHC. Only the lesion observed in the brain of one goat fetus reacted positively with anti-*N. caninum* antibodies, being negative for *T. gondii* (Fig.1).

DISCUSSION

For the authors, the present study is the first description of transplacental transmission of *N. caninum* in goats naturally infected in northeastern, Brazil. In the studied region, just a few studies have shown *N. caninum* infection in goats, such as the studies performed in the state of Bahia and Maranhão, in which the animals showed 15% (58/384) and

17.39% (8/46) seropositivity by IFAT, respectively (Uzêda et al. 2007, Moraes et al. 2011). This scenario shows the lack of studies on *Neospora caninum* infection in goats in northeastern, Brazil.

According to Dubey (2009), it is difficult to estimate the actual losses caused by coccidial infections in small ruminants, because these diseases are sporadic, only a small number of aborted fetuses is submitted for diagnosis and some samples are inappropriate for analysis what impairs the proper diagnosis of the disease etiological agent. Moreover, coccidial infections do not cause clinical disease what differentiates them from bacterial and viral infections, which present clinical signs that facilitate the disease identification by the farmer. The absence of clinical signs may have contributed to the lack of reports of reproductive failures associated with *N. caninum* infection in northeastern, Brazil, despite the fact that the studied region has 90% of the national goat flock (IBGE 2011), which is characterized by extensive rearing systems, inadequate food and sanitary management, low level of management and organization of the productive unit and low technical assistance coverage (Nogueira Filho & Kasprzykowski 2006).

In Brazil, *N. caninum* congenital infection in goats was described in the South and Southeast regions. In the state of Rio Grande do Sul, a Saanen goat showed progressive weakness with ataxia and opisthotonos. The neurological symptoms became more severe three days after birth, when the animal was euthanized and the etiology of the clinical symptoms was confirmed by IHC (Corbellini et al. 2001). Varaschin et al. (2012) described congenital neosporosis in two distinct flocks of goats with history of abortion and weak newborn goat kids in the state of Minas Gerais, southeastern, Brazil.

The lesions observed in the brain and liver samples of a goat fetus evaluated in the present study were similar to those reported in the literature for neosporosis infections (Moreno et al. 2012). However, the lesions found in those samples could also be associated with toxoplasmosis, thus the IHC and PCR assays were crucial for the proper identification of the causative agent. The identification of *Toxoplasma gondii* and *N. caninum* in histological sections is a challenge since it is difficult to visualize their tachyzoites and cysts, especially in cases of low parasitemia. IHC facilitates parasites visualization in tissues (Waree et al. 2007), but this technique may have low sensitivity in natural infections (Moreno

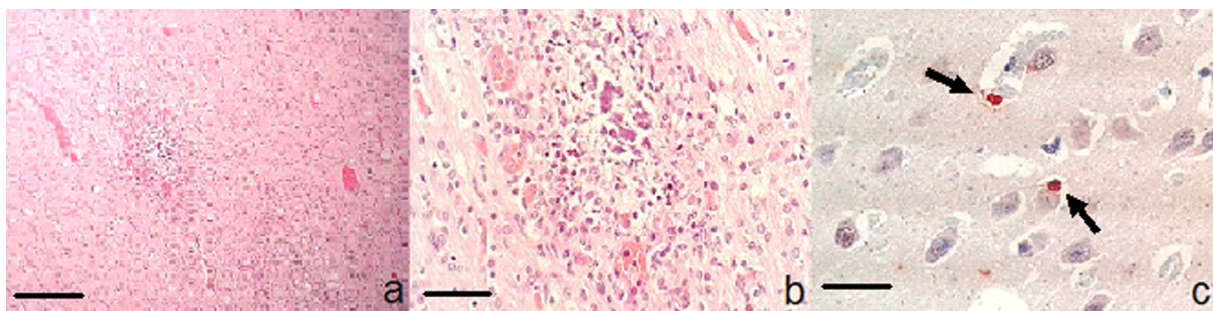


Fig.1. (a) Necrosis with calcification surrounded by glial cells in the brain of a goat infected by *Neospora caninum*. HE, obj.10x and (b) obj.40x; (c) Immunostaining (IHC) of *Neospora caninum* cyst in brain of a goat fetus (arrow), VMRD antibody, obj.100x. Scale bar = 50µm.

Table 2. Absolute and relative frequency of tissue samples from goats and sheep fetuses positive for *Neospora caninum* by PCR, state of Pernambuco, Brazil

| Tissue | Total | PCR | | % |
|--------|-------|-------|------|-------|
| | | Sheep | Goat | |
| Brain | 16 | 1 | 0 | 6.25 |
| Liver | 17 | 4 | 1 | 29.41 |
| Lung | 14 | 0 | 1 | 7.14 |
| Kidney | 17 | 1 | 1 | 11.76 |
| Heart | 14 | 2 | 0 | 14.28 |

et al. 2012) as observed in the present study, in which most of the PCR positive samples were negative by IHC.

Studies have shown a high frequency of histological lesion in the CNS of sheep and goats fetuses infected by *N. caninum* (Kobayashi et al. 2001, Moreno et al. 2012, Sasani et al. 2013). However, in the present study, more liver samples were positive for *N. caninum* by PCR than brain samples (Table 2). Similar finding was reported by González-Warleta et al. (2014) in Spain what suggests that the liver should also be assessed when searching for *N. caninum* in aborted fetuses of small ruminants.

Some samples were not analyzed due to tissue autolysis caused by the time elapsed between fetal death and necropsy what may have hindered the observation of a greater number of characteristic lesions. Buxton et al. (2001) stated that autolysis difficult the histopathological analysis of aborted fetuses' tissues.

Detection of *N. caninum* DNA in some tissue samples of sheep fetuses also suggests the transplacental transmission of this parasite in sheep, although we did not observe tissue lesions compatible with this protozoan in samples. In the state of Mato Grosso do Sul, Pinto et al. (2012) confirmed vertical transmission of *N. caninum* in sheep fetuses and observed mild to moderate perivascular mononuclear infiltrate in heart and diffuse gliosis associated with non-suppurative mononuclear cells in brain. One of the brain samples evaluated by Pinto et al. (2012) had cysts, which were confirmed as *N. caninum* cysts by IHC.

CONCLUSIONS

The results confirmed vertical transmission of *Neospora caninum* in naturally infected goats of northeastern, Brazil.

This study show the importance of including *N. caninum* in investigations of causative agents of abortion in goats flocks in Brazil.

Conflict of interest statement.- The authors declare that they have no conflict of interest.

REFERENCES

- Barr B.C., Anderson M.L., Woods L.W., Dubey J.P. & Conrad P.A. 1992. *Neospora*-like protozoal infections associated with abortion in goats. *J. Vet. Diagn. Invest.* 4(1):365-367.
- Buxton D., Maley S.W., Wright S.E., Rodger S., Bartley P. & Innes E. 2007. *Toxoplasma gondii* and ovine toxoplasmosis: new aspects of an old story. *Vet. Parasitol.* 149:25-28
- Buxton D. 1998. Protozoan infections (*Toxoplasma gondii*, *Neospora caninum* and *Sarcocystis* spp.) in sheep and goats: recent advances. *Vet. Res.* 29(3/4):289-310.
- Buxton D., Wright S., Maley S.W., Rae A.G., Lundén A. & Innes E.A. 2001. Immunity to experimental neosporosis in pregnant sheep. *Parasite Immunol.* 23:85-91.
- Corbellini L.G., Colodel E.M. & Driemeier D. 2001. Granulomatous encephalitis in a neurologically impaired goat kid associated with degeneration of *Neospora caninum* tissue cysts. *J. Vet. Diagn. Invest.* 13:416-419.
- Dubey J.P., Morales J.A., Villalobos P., Lindsay D.S., Blagburn B.L. & Topper M.J. 1996. Neosporosis-associated abortion in a dairy goat. *J. Am. Vet. Med. Assoc.* 208:263-265.
- Dubey J.P. & Schares G. 2011. Neosporosis in animals, the last five years. *Vet. Parasitol.* 180:90-108.
- Dubey J.P., Acland H.M. & Hamir A.N. 1992. *Neospora caninum* (Apicomplexa) in a stillborn goat. *J. Parasitol.* 78:532-534.
- Dubey J.P. 2009. Toxoplasmosis in sheep, the last 20 years. *Vet. Parasitol.* 163:1-14.
- Eleni C., Crotti S., Manuali E., Costarelli S., Filippini G., Moscati L. & Magrino S. 2004. Detection of *Neospora caninum* in an aborted goat foetus. *Vet. Parasitol.* 123:271-274.
- Givens M.D. & Marley M.S.D. 2008. Infectious causes of embryonic and fetal mortality. *Theriogenology* 70:270-285.
- González-Warleta M., Castro-Hermida J.A., Regidor-Cerrillo J., Benavides J., Álvarez-García G., Fuertes M., Ortega-Mora L.M. & Mezo M. 2014. *Neospora caninum* infection as a cause of reproductive failure in a sheep flock. *Vet. Res.* 45:88.
- Hässig M., Sager H., Reitt K., Ziegler D., Strabel D. & Gottstein B. 2003. *Neospora caninum* in sheep: a herd case report. *Vet. Parasitol.* 117:213-220.
- Howe L., Collett M.G., Pattison R.S., Marshall J., West D.M. & Pomroy W.E. 2012. Potential involvement of *Neospora caninum* in naturally occurring ovine abortions in New Zealand. *Vet. Parasitol.* 185:64-71.
- Hurtado A., Aduriz G., Moreno B., Barandika J. & García-Pérez A.L. 2001. Single tube nested PCR for the detection of *Toxoplasma gondii* in fetal tissues from naturally aborted ewes. *Vet. Parasitol.* 102:17-27.
- IBGE 2011. Índice de Produção Pecuária, 2010. Brazilian Institute of Geography and Statistics. <ftp://ftp.ibge.gov.br/Producao_Pecuaria/Producao_da_Pecuaria_Municipal/2011/ppm2011.pdf> Accessed 24 April 2015.
- Kirkbride C.A. 1993. Diagnoses in 1784 ovine abortions and stillbirths. *J. Vet. Diagn. Invest.* 5:398-402.
- Kobayashi Y., Yamada M., Omata Y., Koyama T., Saito A., Matsuda T., Okuyama K., Fujimoto S., Furuoka H. & Matsui T. 2001. Naturally-occurring *Neospora caninum* infection in an adult sheep and her twin fetuses. *J. Parasitol.* 87:434-436.
- Masala G., Porcu R., Daga C., Denti S., Canu G., Patta C. & Tola S. 2007. Detection of pathogens in ovine and caprine abortion samples from Sardinia, Italy, by PCR. *J. Vet. Diagn. Invest.* 19:96-98.
- Menzies P.I. 2011. Control of important causes of infectious abortion in sheep and goats. *Vet. Clin. N. Am., Food Anim. Pract.* 27(1):81-93.
- Mesquita L.P., Nogueira C.I., Costa R.C., Orlando D.R., Bruhn F.R., Lopes P.F., Nakagaki K.Y., Peconick A.P., Seixas J.N., Bezerra P.S., Raymundo D.L. & Varaschin M.S. 2013. Antibody kinetics in goats and conceptuses naturally infected with *Neospora caninum*. *Vet. Parasitol.* 196:327-333.
- Moeller R.B. 2001. Causes of caprine abortion: diagnostic assessment of 211 cases (1991-1998). *J. Vet. Diagn. Invest.* 13:265-270.
- Moraes L.M., Raimundo J.M., Guimarães A., Santos H.A., Macedo Junior G.L., Massard C.L., Machado R.Z. & Baldani C.D. 2011. Occurrence of anti-*Neospora caninum* and anti-*Toxoplasma gondii* IgG antibodies in goats and sheep in western Maranhão, Brazil. *Revta Bras. Parasitol. Vet.* 20:312-317.
- Moreno B., Collantes-Fernández E., Villa A., Navarro A., Regidor-Cerrillo J. & Ortega-Mora L.M. 2012. Occurrence of *Neospora caninum* and *Toxoplasma gondii* infections in ovine and caprine abortions. *Vet. Parasitol.* 187:312-318.
- Nogueira Filho A. & Kasprzykowski J.W.A. 2006. O Agronegócio da Caprinovinocultura no Nordeste Brasileiro. Banco do Nordeste do Brasil, Fortaleza.
- Pinto A.P., Bacha F.B., Santos B.S., Driemeier D., Antoniassi N.A.B., Ribas

- N.L.K.S. & Lemos R.A.A. 2012. Sheep abortion associated with *Neospora caninum* in Mato Grosso do Sul, Brazil. *Pesq. Vet. Bras.* 32:739-742.
- Sasani F., Javanbakht J., Seifori P., Fathi S. & Aghamohammad Hassan M. 2013. *Neospora caninum* as causative agent of ovine encephalitis in Iran. *Pathol. Discov.* 1:5.
- Spilovská S., Reiterová K., Kováčová D., Bobáková M. & Dubinský P. 2009. The first finding of *Neospora caninum* and the occurrence of other abortifacient agents in sheep in Slovakia. *Vet. Parasitol.* 164:320-323.
- Unzaga J.M., Moré G., Bacigalupe D., Rambeaud M., Pardini L., Dellarupe A., De Felice L., Gos M. & Venturini M.C., 2014. *Toxoplasma gondii* and *Neospora caninum* infections in goat abortions from Argentina. *Parasitol. Int.* 63:865-867.
- Uzêda R.S., Pinheiro A.M., Fernández S.Y., Ayres M.C.C., Gondim L.F.P. & Almeida M.A.O. 2007. Seroprevalence of *Neospora caninum* in dairy goats from Bahia, Brazil. *Small Rumin. Res.* 70(1/2):257-259.
- Varaschin M.S., Hirsch C., Wouters F., Nakagaki K.Y., Guimarães A.M., Santos D.S., Bezerra P.S., Costa R.C., Peconick A.P. & Langohr I.M. 2012. Congenital neosporosis in goats from the State of Minas Gerais, Brazil. *Korean J. Parasitol.* 50:63-67.
- Waree P., Ferguson D.J.P., Pongponratn E., Chaisri U. & Sukthana Y. 2007. Immunohistochemical study of acute and chronic toxoplasmosis in experimentally infected mice. *Southeast Asian J. Trop. Med. Public Health* 38:223-231.